

CLINICAL ANATOMY OF THE WRIST AND ELBOW

Bruce D. Steinberg, MD, and Kevin D. Plancher, MD, MS

This article discusses the pertinent anatomy of the wrist and elbow, emphasizing those areas most relevant for clinical diagnosis and treatment. Areas covered include osteology, kinematics, ligamentous constraints, and subcutaneous neurovascular anatomy. For more anatomic detail, it is suggested the reader consult a standard anatomy textbook.

WRIST

The wrist is an anatomic linkage bridging the hand to the forearm. Eight bones of the carpus and the distal ends of the radius and ulna form a complex articulation that allows 3 deg of freedom. The hand, relative to the forearm, can flex and extend, pronate and supinate, and can also deviate radially and ulnarly. In order to have such mobility while also maintaining relative stability, the wrist has a complex configuration of ligaments linking the bones. Malfunction of the wrist occurs when the structural alignment of the bones has changed (i.e., distal radius malunion) or when the ligamentous constraints have been disrupted (i.e., perilunate dislocation).

The distal radius articular surface is biconcave and covered with hyaline cartilage and has two facets divided by a smooth anteroposterior ridge. The lateral scaphoid facet is triangular, whereas the ulnar lunate

From the Jacksonville Orthopaedic Institute, Jacksonville, Florida

CLINICS IN SPORTS MEDICINE

VOLUME 14 • NUMBER 2 • APRIL 1995

299

facet is quadrilateral.⁹ The articular surface has an 11-deg palmar tilt and a 20-deg radial to ulnar inclination.^{3, 18} The radius forms a concave articulation with a convex semicircular ulnar head. With supination and pronation the radius rotates about the stationary ulna.

The distal ulna, however, does not articulate with the carpus. A cushion called the triangular fibrocartilage complex (TFCC) arising from the lunate fossa of the radius covers the distal ulna and inserts distally into the triquetrum, hamate, and the base of the fifth metacarpal. The TFCC acts as a sling for the ulnar aspect of the carpus while also providing stabilization of the distal radioulnar joint (Fig. 1). Palmer has shown that in a neutral position, 60% of the total axial force across the wrist is transmitted through the radius. Removal of the TFCC results in redistribution of the axial load with 95% transmitted through the radius and only 5% through the ulna. Palmer also found that instability of the distal radioulnar joint only occurred after sectioning the attachment of the TFCC to the radius. Sectioning of the pronator quadratus and the distal radioulnar joint capsule did not lead to instability.²⁶

The ulnar aspect of the wrist is stabilized by a combination of three structures: the meniscus homologue of the triangular fibrocartilage complex, the ulnar collateral ligament, and the infratendinous retinaculum of the sixth dorsal compartment.^{25, 32}

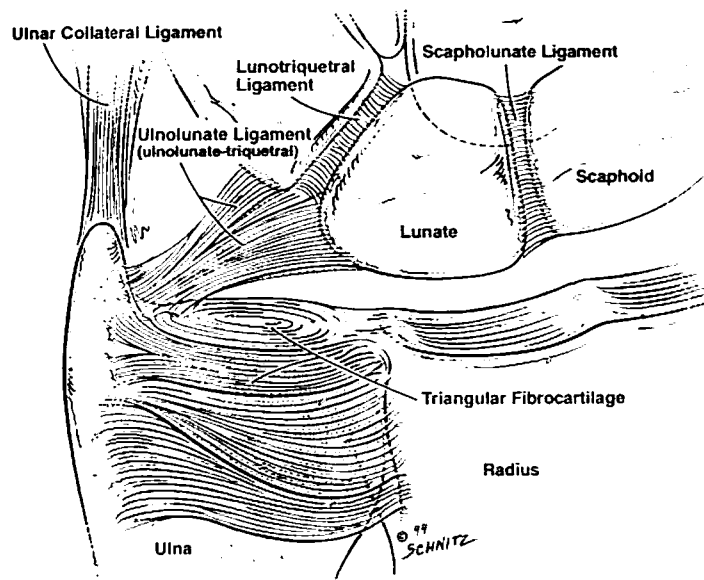


Figure 1. Distal radius and the TFCC seen as a sling for the ulnar aspect of the carpus.

Carpal Bone Kinematics

The osseous linkage between the forearm (radius-triangular fibrocartilage) and bones of the hand (metacarpals) occurs through the eight bones of the wrist (Fig. 2). The articulation of the distal carpal row (trapezium, trapezoid, capitate, hamate) to the metacarpals is extremely stable and the mobility of the wrist, for the most part, occurs in the proximal carpal row (scaphoid, lunate, and triquetrum). After careful kinematic analysis of the wrist, Ruby and colleagues,²⁷ concluded that the proximal row functions as a variable geometric intercalated segment between the distal row and the radius-triangular fibrocartilage. The variable geometry is exemplified by the motions of the wrist in radial and ulnar deviation. In radial deviation the proximal row of the carpus palmar flexes, with the scaphoid and lunate palmar flexing, while the triquetrum moves proximally in relation to the hamate. In ulnar deviation, the proximal row dorsiflexes, with the scaphoid and lunate effectively lengthening by rotating dorsally while the triquetrum moves distal in relation to the hamate (Fig. 3).³¹ These carpal bone motions require a specific interaction of osseous architecture and soft tissue ligamentous constraints.³

The scaphoid, for example, is the bridge across the lunocapitate

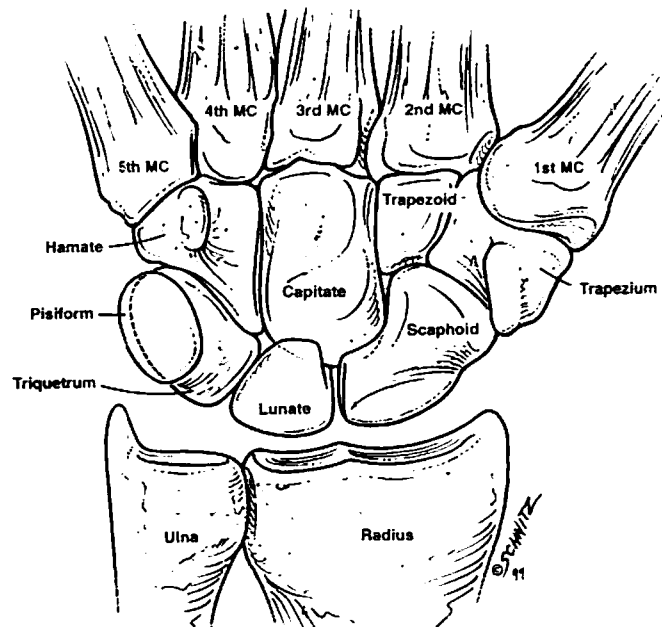


Figure 2. Osteology of the bones (eight carpal bones seen).

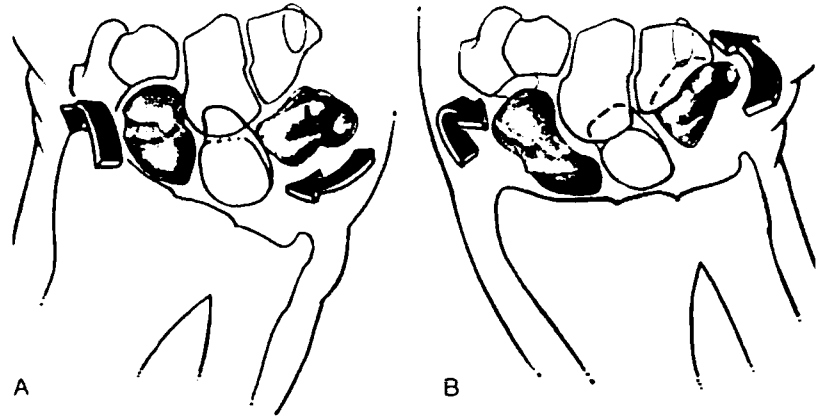


Figure 3. In radial deviation, A, the proximal row is palmar flexed. Scaphoid appears foreshortened, lunate triangular in shape, and triquetrum proximal in relation to the hamate. In ulnar deviation, B, proximal row is dorsiflexed. Scaphoid appears elongated, lunate shape is trapezoidal, triquetrum is distal in relation to the hamate. (From Talesnick J: The bones of the wrist. *In* *The Wrist*. New York, Churchill Livingstone, 1985, p 8; with permission.)

(midcarpal) joint, linking the proximal and distal rows of the carpus. Most of the surface of the scaphoid is covered by hyaline cartilage for articulation with the radius, trapezium, trapezoid, lunate, and the capitate.²⁹ The shape of the scaphoid is closer to a cashew nut than a boat, for which its name is derived (scaphe: Greek for "dug out, trough, or boat").¹⁰ The lunate bone along with the scaphoid forms a concave semilunar articulation with a convex head of the capitate.

On the medial side of the proximal row, the triquetrum articulates with the hamate with a helicoidal-shaped facet.²⁹ As the proximal row of the carpus extends, with ulnar deviation, "the triquetrum glides distally on the hamate as if descending a spiral staircase."²⁹

The capitate is the largest carpal bone and occupies the center of the carpus. It articulates with the second, third, and fourth metacarpals distally, the trapezoid laterally, the hamate medially, and scaphoid-lunate proximally.²⁹ Youm and colleagues³⁴ found that the center of rotation of the wrist in both flexion and extension, and radial and ulnar deviation is within the head of the capitate. Another interesting finding is that the carpal height or distance from the third metacarpal to the radius is always a constant length in a normal wrist no matter the position of the wrist in radial or ulnar deviation. The average ratio of the carpal height length to the length of the third metacarpal was 0.54 with a standard deviation of $\pm .03$.³⁴

Ligaments of the Wrist

In addition to the osseous architecture, carpal stability is maintained by the complex configuration of ligaments linking the bones both dorsally and palmarly. The stronger palmar ligaments of the wrist are divided into two groups, intrinsic ligaments that originate and insert on carpal bones and extrinsic ligaments which cross between the carpal bones and the radius or metacarpals (Fig. 4A).³⁰

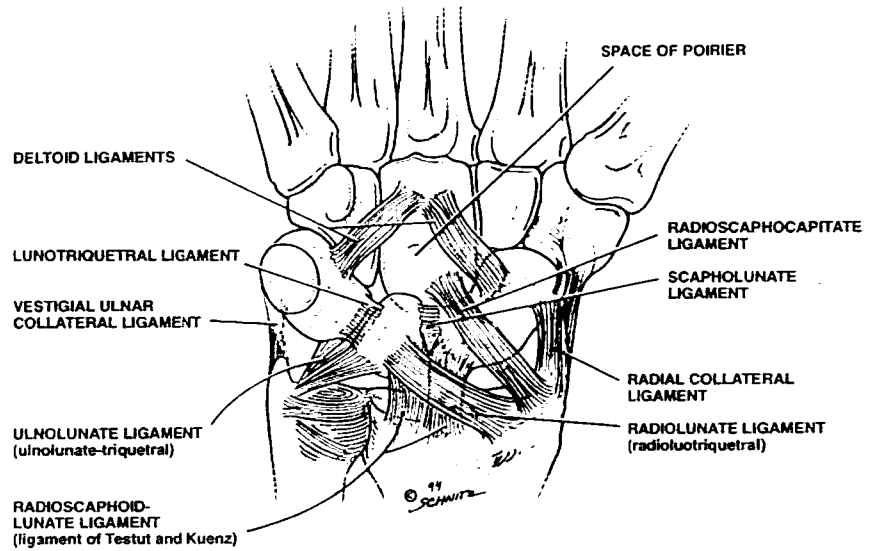
The scapholunate interosseous ligament is one of the key intrinsic ligaments of the wrist and has been studied extensively (Fig. 4B). The scapholunate interosseous ligament (SLL) is among the most frequently injured wrist ligaments and is associated with a number of important clinical disorders (i.e., SLL diastasis and carpal instability). Logan and colleagues have found that the yield strength of the palmar SLL was approximately twice that of the dorsal SLL.^{11, 12} This anatomic finding may explain why ganglions arising from the scapholunate joint occur dorsally² and rarely palmarly. The dorsal extrinsic ligaments are thin, few in number, and are functionally and structurally reinforced by the floor and septi of the fibrous tunnels through which the extensor tendons pass.¹⁹ The extrinsic palmar ligaments (Fig. 4A) form two inverted V-shaped ligamentous complexes. The capitate is the apex distally, and the lunate is the apex proximally.³¹ The space between these two complexes forms an inherently weak area filled with synovial out-pouching overlying the capitollunate joint, called the Space of Poirier.¹⁷

The palmar extrinsic ligaments which arise from the radius help to control the kinematics of the wrist and particularly the scaphoid. The radioscapnocapitate ligament acts as a sling at the waist of the scaphoid. Taleisnick³¹ has pointed out that the scaphoid rotates on this ligament as a gymnast balances on a horizontal bar while executing a hip circle (Fig. 5). The strongest palmar extrinsic ligament, the radiolunate ligament,¹² is particularly important in scaphoid rotation and is tense at the extremes of wrist motion (Fig. 4B).^{30, 31}

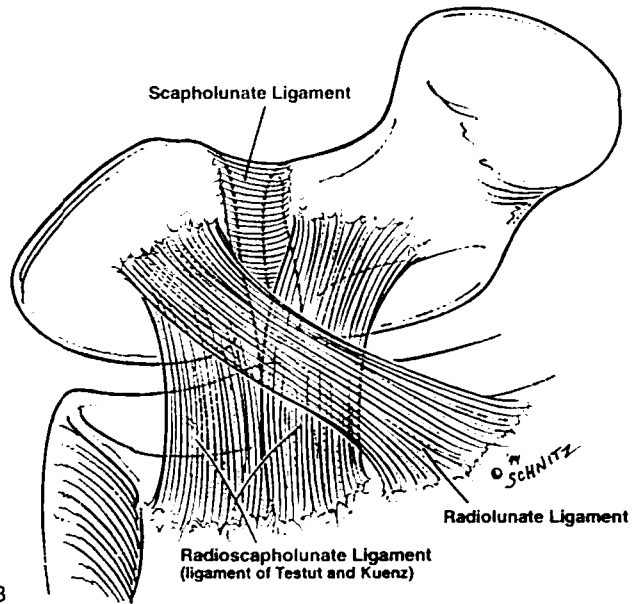
On the ulnar aspect of the wrist, the triquetrum is the point of convergence of the ulnocarpal meniscus homologue, the palmar radiolunotriquetral ligament, the capitotriquetral ligament and the dorsal intercarpal ligament. These ligaments act together to control the motion on the triquetrum as it moves on a helicoidal articulation with the hamate, proximally in radial deviation and distally in ulnar deviation.^{30, 31, 35}

Subcutaneous Anatomy

In any open surgical or arthroscopic approach to the wrist, the surgeon must be aware of the anatomic location of neurovascular struc-



A



B

Figure 4. A, Extrinsic and intrinsic palmar ligaments of the wrist. The space of Poirier well seen. B, The anatomy of the scapholunate interosseous ligament.

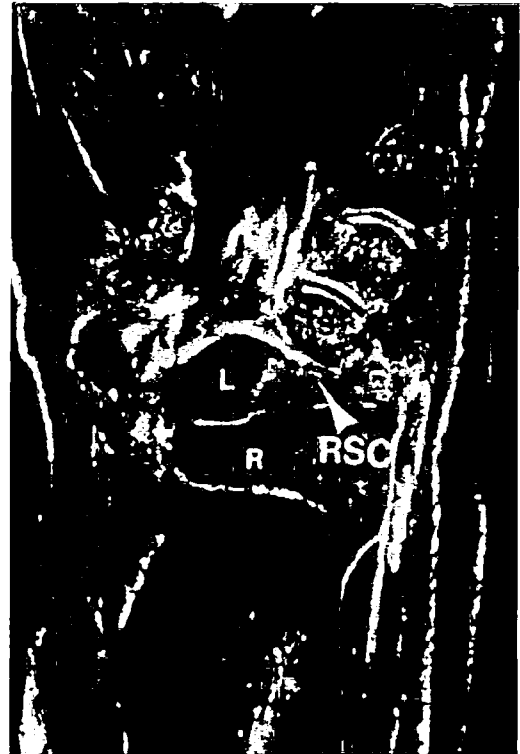


Figure 5. Radioscaphocapitate ligament (*RSC*). Palmar half, coronal section; obliquely across waist of scaphoid (*S*); *R*, Radius; *L*, Lunate; *T*, Trapezium. (From Talesnick J: The ligaments of the wrist. In *The Wrist*. New York, Churchill Livingstone, 1985, p 27; with permission.)

tures. The superficial branch of the radial nerve (SBRN), the lateral antebrachial cutaneous nerve (LABCN), the dorsal sensory branch of the ulnar nerve (DSBUN), and the palmar cutaneous branch of the median nerve (PCBMN) are particularly at risk of injury during operative procedures on the wrist. On the radial aspect of the forearm the superficial branch of the radial nerve (SBRN) enters the subcutaneous tissue a mean 9.0 cm proximal to the radial styloid between the brachioradialis and the extensor carpi radialis longus.¹ The SBRN bifurcates a mean distance of 4.2 cm proximal to Lister's Tubercle. The dorsal branch crosses distally and bifurcates again a mean distance of 0.4 cm proximal to Lister's Tubercle.²⁸ MacKinnon and colleagues¹⁵ found that the LABCN overlapped the SBRN completely in 38% of their specimens.

Steinberg and coworkers (Fig. 6) define a trapezoidal safe zone deep to the LABCN, where the mean distance from the radial styloid to the radial artery is 7.5 mm and the mean square area of the safe zone is 0.68 cm².²⁸

The DSBUN arises 5 to 8 cm proximal to the ulnar styloid. The nerve exits under cover of the flexor carpi ulnaris where it runs dorsally to course around the ulna, piercing deep fascia and interverting the

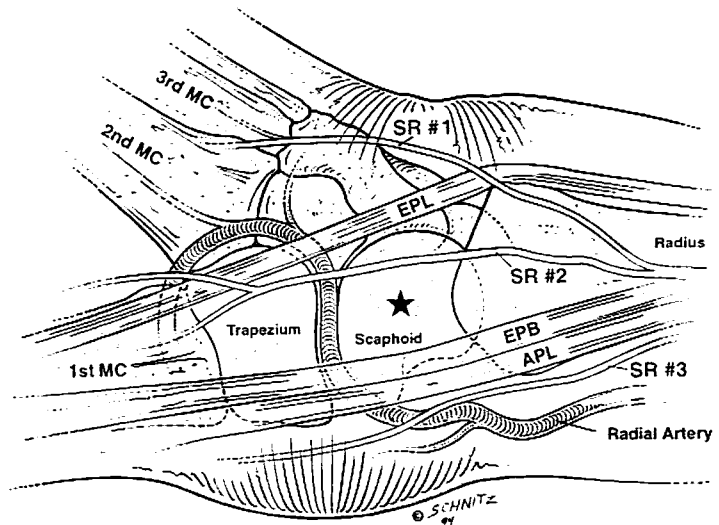


Figure 6. Demonstration of the safe zone for percutaneous pinning of the radial side of the wrist.

dorsal ulna aspect of the hand.^{4, 5, 13} Lourie and colleagues found a transverse radioulnar branch arising from the DSBUN. The nerve had two patterns: type I arose 1.3 cm proximal to the ulnar styloid and type II 0.5 cm distal to the styloid (Fig. 7).¹³

The PCBMN arises approximately 5 cm proximal to the wrist crease and then attaches itself to the undersurface of the antebrachial fascia immediately under the ulnar margin of the flexor carpi radialis tendon. The nerve then enters the palm in a tunnel between the superficial and deep layers of the transverse carpal ligament dividing into branches that innervate the base of the thenar eminence and the skin immediately radial to the axis of the fourth ray in the palm.³¹

Understanding recent investigations coupled with a basic understanding of the intricate anatomy of the wrist will allow for safe passage in and out of the wrist during surgery.

ELBOW

The elbow is an anatomic linkage bridging the shoulder to the hand, acting both to enhance flexibility in hand placement and to transmit and absorb generated forces. The elbow has 2 deg of freedom (supination-pronation and flexion-extension). The circular radial head and spheric capitellum articulation allows pronation and supination, while a "tongue and groove" articulation of the humeral ulnar joint creates a very stable

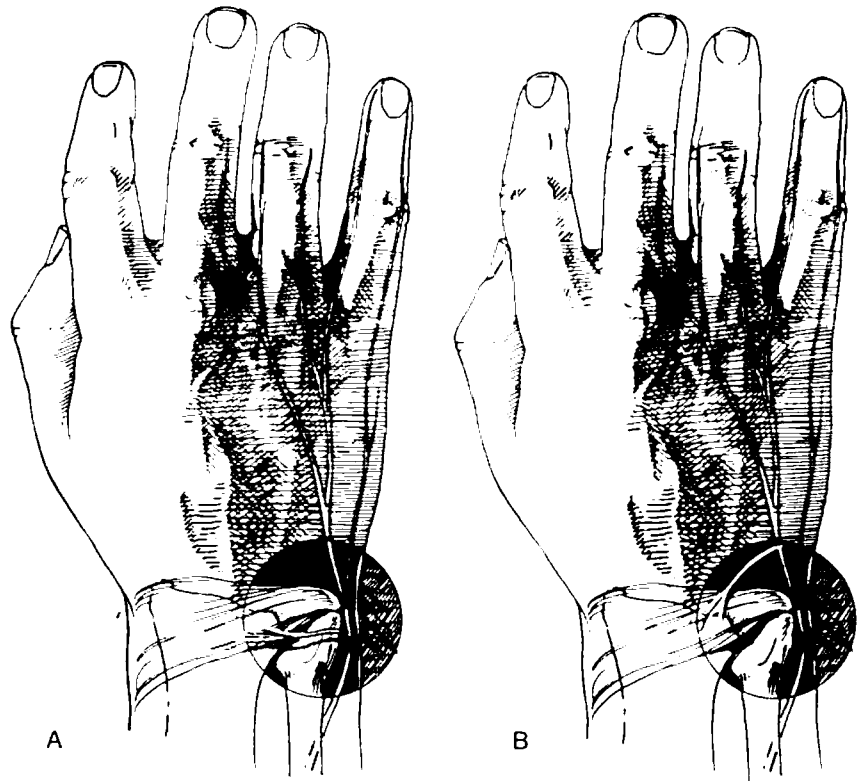


Figure 7. The transverse radioulnar sensory branch. A, Type 1 presentation; B, Type 2 recurrent presentation. (From Lourie GM, King J, Kleinman WB: The transverse radioulnar branch from the dorsal sensory ulnar nerve: Its clinical and anatomical significance further defined. *J Hand Surg* 19A:243, 1994; with permission.)

configuration allowing flexion-extension.^{4, 9, 20, 21} The axis of rotation for pronation-supination is the center of the radial head, whereas the axis of rotation for flexion-extension is a line passing through the center of the trochlea.²¹

The lateral epicondyle, medial epicondyle, and olecranon are easily palpable landmarks of the elbow (Fig. 8). These three structures form an inverted triangle when the elbow is flexed 90 deg. The lateral epicondyle, located just above the capitellum, is the origin of the supinator-extensor muscle group; however, the more prominent medial epicondyle is the origin for the flexor-pronator muscle group. In a thin individual, one can palpate the medial and lateral supracondylar ridges of the humerus. The lateral supracondylar ridge separates the brachioradialis and extensor carpi radialis longus anteriorly and the triceps posteriorly. The medial supracondylar ridge separates the brachialis, median nerve, and brachial artery anteriorly and the triceps and ulnar nerve posteriorly.^{4, 6, 20}

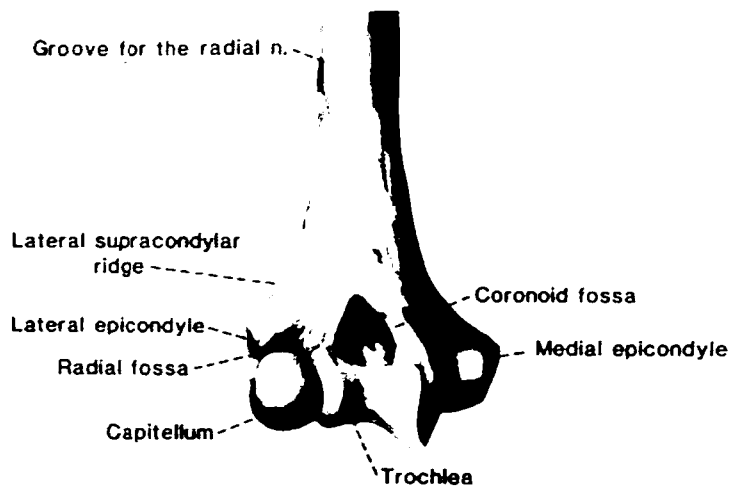


Figure 8. The bony landmarks of the anterior aspect of the distal humerus. (From Morrey BF: *The Elbow and Its Disorders*. Philadelphia, W.B. Saunders, 1993, p 20; with permission.)

Osteology of the Elbow

The stability of the elbow arises from a combination of the articulation of the ulna and humerus as well as ligamentous constraints. The ulnohumeral joint resembles a hinge which allows flexion and extension. The trochlea of the humerus forms a spool-like surface that articulates with the groove of the semilunar notch of the ulna (Fig. 9). There is an approximate 6 to 8 deg valgus tilt of the trochlea articulation with respect to the long axis of the humerus. This valgus tilt in combination with a 4 deg valgus angulation of the semilunar notch relative to the ulnar shaft creates the valgus carrying angle of the normal elbow. In males the mean carrying angle is 11 to 14 deg, whereas in the female it is 13 to 16 deg.^{14, 20}

The radiocapitellar and proximal radioulnar joint allows axial rotation of 180 deg. Hyaline cartilage covers 240 deg of the outside circumference of the radial head, which allows articulation with the proximal ulna at the radial notch. The depressed radial head articulates with the spherical capitellum maintaining the center of rotation within the capitellum despite flexion-extension, pronation-supination.^{16, 20, 22}

Ligaments of the Elbow

In addition to bony architecture of the ulnohumeral joint, the elbow is stabilized by medial and lateral ligamentous complexes. The medial collateral ligament complex is composed of three parts: a strong anterior

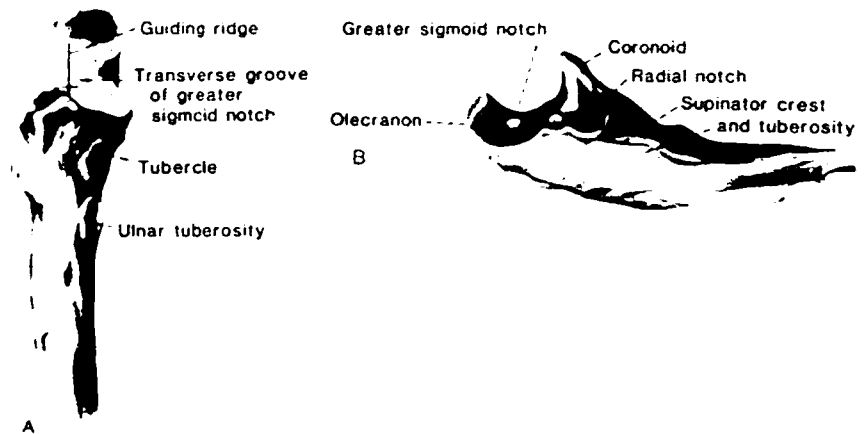


Figure 9. Anatomy of the elbow. A, Anterior aspect of the proximal ulna demonstrating the greater sigmoid fossa with the central groove. B, Lateral view with landmarks. (From Morrey BF: *The Elbow and Its Disorders*. Philadelphia, W.B. Saunders, 1993, p 22; with permission.)

bundle, a posterior bundle, and transverse ligament (Fig. 10). The anterior bundle of the medial collateral ligament is the major constraint of valgus instability of the elbow.^{7, 8, 21, 26} The origin of this bundle is the inferior surface of the medial epicondyle and its insertion is at the medial aspect of the coronoid process of the ulna.^{8, 26}

The lateral ligamentous complex is composed of the lateral collateral ligament, the annular ligament, accessory lateral collateral ligament, and the lateral ulnar collateral ligament (Fig. 11). The radial collateral ligament arises from the lateral epicondyle and terminates into the annular ligament. The annular ligament wraps around four fifths of the radial head and contributes to stability to the proximal radioulnar articulation. The annular ligament is stronger and has a more extensive attachment




Figure 10. Medial collateral ligament (MCL) of the elbow. Classic orientation of the MCL, including anterior and posterior bundles, and the transverse ligament. (From Morrey BF: *The Elbow and Its Disorders*. Philadelphia, W.B. Saunders, 1993, p 29; with permission.)

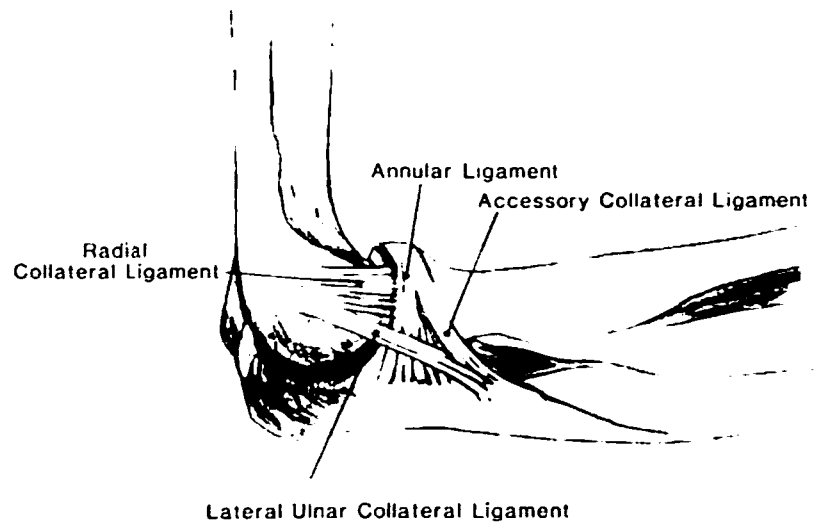


Figure 11. More detailed representation of the radial collateral complex showing a portion termed the radial collateral ligament that extends from the humerus to the annular ligament. (From Morrey BF: *The Elbow and Its Disorders*. Philadelphia, W.B. Saunders, 1993, p 30; with permission.)

to the ulna posteriorly than anteriorly.^{21, 23, 25} The lateral ulnar collateral ligament arises from the lateral epicondyle and inserts into the tubercle of the crest of the supinator on the ulna. Morrey and colleagues believe that the lateral ulnar collateral ligament represents the primary lateral stabilizer of the elbow.^{20, 21, 25}

Subcutaneous Anatomy of the Elbow

The anatomic location of the neurovascular structures about the elbow are extremely important in any open surgical or arthroscopic approach to the elbow. The most important structures at risk are the radial, median, and ulnar nerves as well as the brachial artery. The radial nerve penetrates the lateral intramuscular septum at the distal one third of the humerus. It then descends anterior to the lateral condyle between the brachialis muscle medially and the brachioradialis and extensor carpi radialis longus laterally. The nerve then crosses anterior to the radial capitellar joint and divides into the posterior interosseous nerve and the superficial branch of the radial nerve. The posterior interosseous nerve diverges laterally and posteriorly passing under the proximal superficial edge of the supinator muscle called the arcade of Frochse. The superficial branch continues distally under cover of the brachioradialis muscle (Fig. 12).^{4-6, 24}

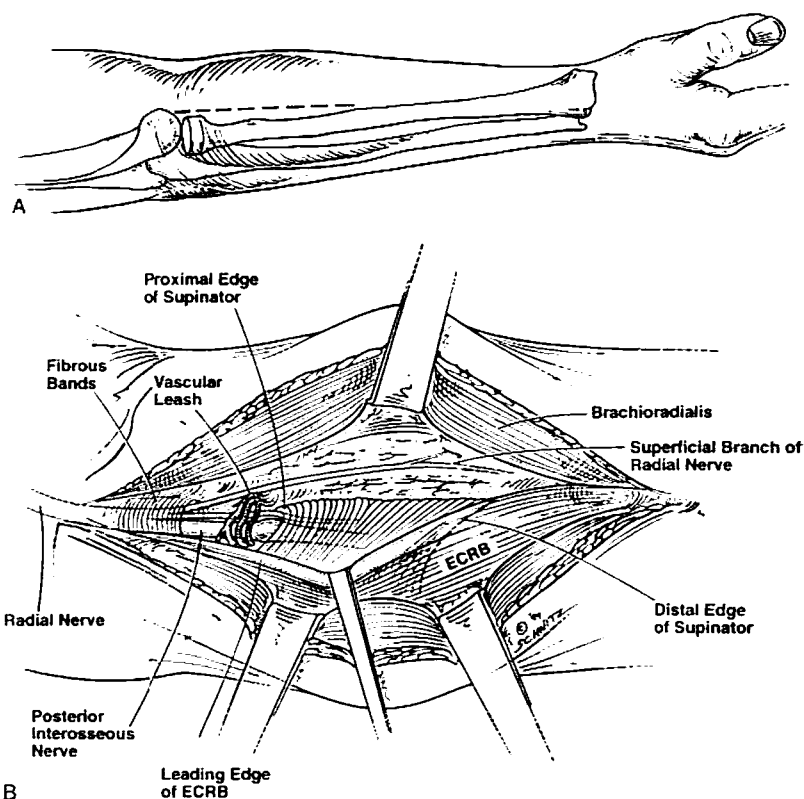


Figure 12. A, Surgical approach to the proximal forearm in a patient with radial tunnel syndrome. B, Radial nerve compression in the forearm. Decompression of the arcade of Frochse (superficial edge of the supinator).

The median nerve and brachial artery lie medial to the brachialis in the arm. The median nerve is medial to the brachial artery at the level of the antecubital fossa where both pass under cover of the bicipital aponeurosis. The brachial artery then divides into two main branches, the ulnar artery coursing deep to the ulnar head of the pronator teres and the radial artery coursing superficial and lateral to the pronator teres insertion on the radius. Meanwhile, the median nerve crosses through the ulnar and humeral heads of the pronator teres.^{4, 6, 24}

The ulnar nerve pierces the medial intramuscular septum at the middle of the arm descending anterior to the medial head of the triceps. The nerve then enters the cubital tunnel just inferior to the medial epicondyle and medial to the olecranon. The nerve continues to course distally between the humeral and ulnar heads of the flexor carpi ulnaris.^{4, 24}

Three cutaneous nerves also cross the elbow and can be injured

during surgery. The medial antebrachial cutaneous nerve with the basilic vein penetrates the brachial fascia along the medial aspect of the arm at the junction of the middle and distal third. The nerve courses distally in the subcutaneous tissue just anterior to the medial epicondyle of the elbow. The lateral antebrachial cutaneous nerve arises from the musculocutaneous nerve, between the biceps brachii and the brachialis muscles. The nerve pierces the deep fascia at the proximal lateral aspect of the antecubital fossa and continues distally overlying the midportion of the extensor forearm muscle mass. The nerve passes behind the cephalic vein and divides into anterior and posterior branches. The branches supply sensation to the radial aspect of the forearm, wrist, and hand. The third cutaneous nerve to cross the elbow is the posterior antebrachial cutaneous nerve arising from the radial nerve. This nerve penetrates the brachial fascia 7 cm proximal to the elbow. The nerve then descends posterior to the lateral epicondyle overlying the anconeus and extensor digitorum communis muscles.^{4, 24}

SUMMARY

For the orthopedist, the design and execution of surgical procedures requires a thorough understanding of anatomy. The goal of this article is to provide an overview of the pertinent surgical anatomy of the wrist and elbow. Operative techniques improve with advancing technologic breakthroughs and greater understanding of anatomy. Today's orthopedic surgeon is required to remain current on this expanding information base; this information will allow for a better understanding of common and overuse injuries of the wrist, forearm, and elbow.

References

1. Abrams RA, Brown RA, Botte MJ: The superficial branch of the radial nerve: An anatomical study with surgical implications. *J Hand Surg* 17A:1037-1041, 1992
2. Angelides AL, Wallace PF: The dorsal ganglion of the wrist: Its pathogenesis, gross and microscopic anatomy and surgical treatment. *J Hand Surg* 1A:228-235, 1976
3. Cooney WP, Garcia-Elias M, Dobyns JM, et al: Anatomy and Mechanics of Carpal Instability—Surgical Rounds for Orthopaedics. 1989, pp 15-22
4. Hollinshead WH: *Anatomy for Surgeons—The Back and Limbs*. Philadelphia, JB Lippincott, 1982, pp 341-562
5. Hollinshead WH, Markee JE: The multiple innervation of limb muscles in man. *J Bone Joint Surg* 28A:721-731, 1946
6. Hoppenfield S, DeBoer P: *Surgical Exposures in Orthopaedics: The Anatomical Approach*. Philadelphia, JB Lippincott, 1984, pp 101-108
7. Jobe FW, Kvitne RS: Reconstruction of the ulnar collateral ligament of the elbow. *Techniques Ortho* 6:39-42, 1991
8. Jobe FW, Stark H, Lombardo SJ, et al: Reconstruction of the ulnar collateral ligament in athletes. *J Bone Joint Surg* 68A:1158-1163, 1986

9. Jupiter JB, Mehne DK: Trauma to the adult elbow and fractures of the distal humerus. *In* Browner BD: Skeletal Trauma, vol 2. Philadelphia, WB Saunders, 1992, pp 1125-1126
10. Kaplan EB, Talesnik J: The wrist. *In* Functional and Surgical Anatomy of the Hand, ed 2. Philadelphia, JB Lippincott, 1965, p 153
11. Logan SE, Nowak MD: Intrinsic and extrinsic wrist ligaments: Biomechanical and function differences. *ISA Transactions* 27:37-41, 1987
12. Logan SE, Nowak MD, Gould PL, et al: Biomechanical behavior of the scapholunate ligament. *Biomedical Sciences Instrumentation* 22:81-85, 1986
13. Lourie GM, King J, Kleinman WB: The transverse radioulnar branch from the dorsal sensory ulnar nerve: Its clinical and anatomical significance further defined. *J Hand Surg* 19A:241-245, 1994
14. London JT: Kinematics of the elbow. *J Bone Joint Surg* 63A:529-535, 1981
15. MacKinnon SE, Dellon AL: The overlap pattern of the lateral antebrachial cutaneous nerve and the superficial branch of the radial nerve. *J Hand Surg* 10A:522-526, 1985
16. Martin BF: The annular ligament of the superior radial ulnar joint. *J Anat* 52:473-481, 1958
17. Mayfield JK: Wrist ligamentous anatomy and pathogenesis of carpal instability. *Orthop Clin North Am* 15:209-216, 1984
18. McMurty RY, Jupiter JB: Fracture of the distal radius. *In* Browner BD (ed): Skeletal Trauma, vol. 2. Philadelphia, WB Saunders, 1992, p 1074
19. Mizuseki T, Ikuta Y: The dorsal carpal ligaments: Their anatomy and function. *J Hand Surg* 14B:91-98, 1989
20. Morrey BF: The elbow and its disorders. Philadelphia, WB Saunders, 1993, pp 16-52
21. Morrey BF, Chao EY: Passive motion of the elbow joint. *J Bone Joint Surg* 58A:501-509, 1976
22. Nestor BJ, O'Driscoll SW, Morrey BF: Ligamentous reconstruction for posterolateral rotatory instability of the elbow. *J Bone Joint Surg* 74A:1235-1241, 1992
23. Netter FH: Musculoskeletal System: Anatomy, Physiology, and Metabolic Disorders. Summit, CIBA-GEIGY, 1987, pp 21-53
24. O'Driscoll SW, Bell DF, Morrey BF: Posterolateral rotatory instability of the elbow. *J Bone Joint Surg* 73A:440-446, 1991
25. O'Driscoll SW, Jalszynski R, Morrey BF, et al: Origin of the medial ulnar collateral ligament. *J Hand Surg* 17A:164-168, 1992
26. Palmer AK, Werner FW: The triangular fibrocartilage complex of the wrist: Anatomy and function. *J Hand Surg* 6:153-162, 1981
27. Ruby LK, Cooney WP, An KN: Relative motion of selected carpal bones: A kinematic analysis of the normal wrist. *JHS* 13A:1-9, 1988
28. Steinberg BD, Plancher KD, Idler RS: Percutaneous Kirschner wire fixation through the snuff box: An anatomical study. *J Hand Surg* 1995, in press
29. Taleisnick J: The bones of the wrist. *In* Taleisnick J (ed): The wrist. New York, Churchill Livingstone, 1985, pp 2-11
30. Taleisnick J: The ligaments of the wrist. *J Hand Surg* 1A:110-118, 1976
31. Taleisnick J: The ligaments of the wrist. *In* Taleisnick J (ed): The wrist. New York, Churchill Livingstone, 1985, pp 2-11
32. Taleisnick J: The palmar cutaneous branch of the median nerve and the approach to the carpal tunnel. *J Bone Joint Surg* 55A:1212-1217, 1973
33. Taleisnick J, Gelberman RH, Miller BW: The extensor retinaculum of the wrist. *J Hand Surg* 9A:495-501, 1984
34. Youm Y, McMurtry RY, Flatt AE: Kinematics of the wrist. *J Bone Joint Surg* 60A:423-431, 1978
35. Zancolli EA, Cozz EP: Atlas of Surgical Anatomy of the Hand. New York, Churchill Livingstone, 1992, p 422

Address reprint requests to

Bruce D. Steinberg, MD
 Jacksonville Orthopaedic Institute
 1325 San Marco Blvd.
 Jacksonville, FL 32207