Techniques in Orthopaedics®
21(4):276–282 © 2006 Lippincott Williams & Wilkins, Inc.

Open Lateral Epicondylectomy: A Simple Technique Update for the 21st Century

Kevin D. Plancher, M.D., M.S.,*‡ and Shariff K. Bishai, D.O., M.S.†‡

Summary: Lateral epicondylitis is the most common cause of lateral sided elbow pain in adults. While conservative treatment can relieve the symptoms, recalcitrant pain often requires surgical intervention. Various methods have been described including open, mini-open, percutaneous, and partial lateral epicondylectomy. Partial lateral epicondylectomy as described by Froimson is a tried and true methods that has been proven to be an excellent treatment for lateral epicondylitis. This article provides a systematic approach to the treatment of lateral epicondylitis. **Key Words:** Lateral epicondylitis—Lateral epicondylosis—Froimson technique—Lateral epicondylectomy.

Epicondylar pain with tenderness and its related disability has become the accepted standard symptoms of a syndrome called tennis elbow for over a century.[31,32] The condition is much more common in nonathletes than in tennis players.[6] Studies have shown that the pathoanatomical changes that persist with tennis elbow are of an angiofibrotic neovascularization process and therefore it is a misnomer to label this problem as epicondylitis and therefore it should be known as an epicondylosis. Epicondyliosis or epicondylalgia, is seen 7 to 10 times more often on the lateral than on the medial side of the elbow. Tennis elbow affects patients in the fourth and fifth decades of life[6] and is characterized by tenderness and pain at the involved humeral epicondyle, aggravated by wrist extension if lateral and by wrist flexion if the medial side is affected. Treatment regimes will be discussed. Elbow symptoms similar to tennis elbow in young adolescents are associated with conditions such as instability, osteochondritis dissecans, or tumors and should be investigated with great haste.

From the *Albert Einstein College of Medicine, New York, New York; †Beth Israel Medical Center, New York, New York; and the ‡Plancher Orthopaedics and Sports Medicine, Orthopaedic Foundation for Active Lifestyles, Cos Cob, Connecticut.

Address correspondence and reprint requests to Kevin D. Plancher, MD, MS, Orthopaedic Foundation for Active Lifestyles, 31 River Rd., Cos Cob, CT 06807. E-mail: kplancher@plancherortho.com

HISTORY, PHYSICAL EXAM, AND DIFFERENTIAL DIAGNOSIS

Patients affected by lateral epicondylosis complain of lateral sided elbow pain and usually have some type of repetitive behavior with the arm. The point of maximal tenderness in the lateral epicondylosis is directly over the epidoncyle; whereas in radial tunnel syndrome, tenderness in severe where the radial nerve is palpated through the mobile muscle mass just distal to the radial head.[2,14,25] In radial tunnel syndrome, pain is produced by resisting middle finger extension or by forearm supination with the elbow extended.[28] The typical pain of tennis elbow or lateral epicondylosis is reproduced by extending the wrist and long finger against resistance. Electromyographic confirmation of radial nerve involvement is diagnostic of tunnel syndrome, but a negative examination does not rule out the problem.

PATHOANATOMY

Heyse-Moore[18] has shown by anatomic dissection studies that the origins of extensor carpi radialis brevis and the superficial part of the supinator are blended and inseparable, both originating from the lateral epicondyle, elbow joint capsule, and articular ligament. They theorized that the relief of tennis elbow symptoms that followed surgical division of the fibrous arch of supinator was the result of lessening of tension at the lateral

epicondyle rather than a radial nerve decompression, which was popular at the time. They advocated abandonment of the concept that recalcitrant tennis elbow is a radial tunnel syndrome.

Several different pathologic lesions at the elbow have been described in the literature to explain the signs and symptoms of tennis elbow,[37] and each hypothesis has generated an operative technique to be used in cases resistant to conservative management. The question as to the true cause of pain has led to the various techniques in the treatment of lateral epicondylosis. Synovial fringes have been excised,[3,31,36,39,41] the orbital ligament sectioned,[3,5,12,27,39] the radial nerve decompressed,[18,20,22,23,25,42,45] diseased articular cartilage excised,[30] tendon lengthened[7,11] or released,[1,3,12,15,17,26,30,39,40,43,47] tendon excised,[33,34] tendon origin repaired,[2,5,8,10,16,21,31–34] or combinations of these techniques have been used.[35,46]

Our observations have been consistent with the findings reported in studies by Coonrad and Hooper[8] and by Nirschl.[31] These authors confirmed earlier works by Goldie [17] and Cyriax,[9] which demonstrated that the lesion in tennis elbow is a tear in the common extensor at the epicondyle. These tears are produced by mechanical overload in sports or at work in degenerating or aging tendon fibers. The tears range in magnitude from microscopic to gross rupture or avulsion. Therefore, our surgical management, which will be described later on in this article, is designed to excise the damaged tendon fibers, repair the defect, and promote the firm reattachment to bone of the extensor or flexor origin.

NONOPERATIVE TREATMENT

Tennis elbow may respond to nonsurgical treatment with an initial period of rest followed by a program of exercises to strengthen the forearm and hand muscles when symptoms have been long standing. Patients presenting with severe disability can benefit from nonoperative treatment as much as those who have symptoms only related to exertion. Various modalities of heat therapy, including an electric heating pad, ultrasound, or diathermy supplement anti-inflammatory medication, such as the salicylates or nonsteroidal drugs, can be used to quell acute pain and swelling. Manipulation therapy has been proposed. Local injections of a steroid preparation and local anesthetic into the tender tear are administered to limit to one injection. As recovery is noted, a forearm support band[13] is prescribed for use during the sport or occupational activity that provokes pain. For tennis players, changes in racquet size, weight, or composition and a course of professional instruction may be recommended.[32]

DIAGNOSTIC IMAGING

Plain X-rays are not necessarily indicated early in the management of tennis elbow unless there is limitation of motion, angular deformity, or a palpable mass. Plain X-rays may also be advisable to rule out other problems if the patient with typical clinical symptoms and signs of lateral epicondylosis does not respond to an injection and occupational hand therapy. In the usual case of lateral epicondylosis, a bony thickening or osteophyte formation may be noted at the lateral epicondyle extensor origin, sometimes a poorly circumscribed soft tissue calcification or ossification may be seen. A special radiographic view directing the X-ray beam along the shaft of the humerus, the so-called "gunsight" view may be helpful to identify abnormalities in the bone. Other imaging studies including ultrasound, magnetic resonance imaging (MRI), and are recommended in the management of tennis elbow for professional athletes and patients with recalcitrant symptoms.

The use of an MRI can be helpful to predict outcome. An inflamed epicondyle can often respond to conservative treatment whereas an avulsed or necrotic extensor carpi radialis brevis (ECRB) will require surgical intervention. It is the partial tear of the ECRB that requires patience to await the neovascularization process. Not all lateral epicondylosis is the same in every patient and therefore managing expectations can be easier in certain cases with the use of an MRI or an experienced ultrasonagrapher.

INDICATIONS FOR OPERATIVE TREATMENT

Surgical management is indicated in the 5% to 10% of cases in which nonoperative treatment fails to provide lasting relief in a reasonable length of time. Assessment of the individual patient's functional requirements provides the critical factor in timing. Some may be willing and able to endure a year or more of pain and disability, whereas others, particularly professional athletes and manual workers, are given the option of earlier surgical repair to shorten the period of disability.

There is no merit in a prolonged delay in offering surgical treatment in the face of persisting symptoms. This author's own experience is similar to that of Newey and Patterson, who found that pain relief was significantly better in those patients with the shorter duration of preoperative symptoms.[29]

ANATOMY

The tendon of the common extensor originates from the lateral humeral epicondyle. This conjoined tendon

consists of fibers of the ECRB, extensor digitorum communis (EDC), extensor digiti minimi (EDM), and extensor carpi ulnaris (ECU), as well as part of the origin of the supinator. In considering the pathology and treatment of tennis elbow, one is interested primarily in that portion of the common tendon belonging to the ECRB, because the tears associated with tennis elbow are found in these fibers. The long radial wrist extensor, extensor carpi radialis longus (ECRL), arising more proximally along the supracondylar ridge of the humerus is often spared (Fig. 1).

The ECRB may arise in a small part from the radial collateral ligament of the elbow joint, and this ligament in turn attaches to the annular or orbicular ligament containing the radial head. This interrelationship of parts has been used by some authors[3–6,31,32,34] as the rationale to explore the elbow joint surgically for this lesion. In our experience, this is both unnecessary and undesirable.[46]

TYPES OF OPERATIONS

The various operations for tennis elbow may be classified into four types: 1) those that repair the extensor origin after excision of the torn tendon, granulation tissue, and part of the epicondyle;[5,8,13,16,31–33] 2) those that relieve tension on the common extensor by fasciotomy or by direct release by dissection of the extensor origin from the epicondyle[1,17,19,26,40,43,47] or by lengthening the extensor carpi radialis brevis tendon distally[7,15]; 3) those directed at the radial nerve, either by denervating the outside of the elbow by severing sensory fibers[22] or by decompressing the posterior interosseous nerve;[25,28,38,45] and 4) those that involve intra-articular procedures such as partial or complete division of the orbicular ligament[3,4,6,12,27,39] reshaping of the radial head or synovectomy,[30,36,41] separately or in combination with fasciotomy, or release of the extensor origin.

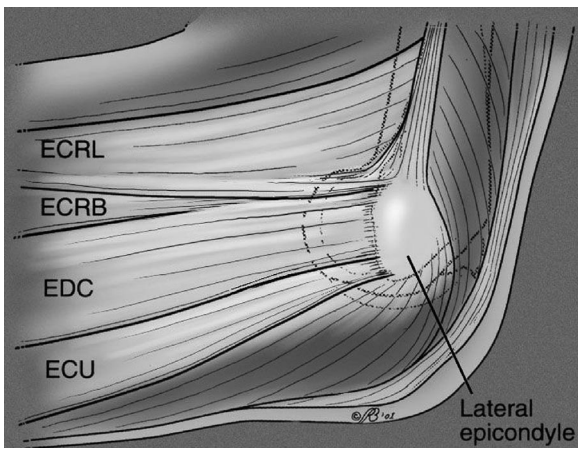

FIG. 1. Anatomy of the lateral side of the elbow showing the site of the common extensor origin tear found in cases of tennis elbow (Copyright Kevin D. Plancher, M.D.).

Because the lesion in tennis elbow is extra-articular, in our opinion the procedures in category 4 are not warranted. The synovitis with effusion that may be present will often resolve after an extensor origin repair.[8] The procedure of denervation was published with only 3 cases,[22] so it also cannot be recommended. The uncommon problem of posterior interosseous nerve compression (radial tunnel syndrome) is a condition other than tennis elbow; thus, those operative procedures devised to relieve it will not be described here.

Although fasciotomy and extensor (or flexor) release have been lauded by their proponents as simple operative methods.[43] We stopped doing these procedures after finding that loss of strength often resulted, hampering effectiveness especially in the more advanced player in tennis and other activities. We also found it difficult to determine the necessary extent of the fasciotomy because the transaction has to be done across normal tendon fibers. The idea of relieving the pain resulting from a partly torn tendon by creating a larger defect in tendon and fascia to help increase strength does not seem to follow a careful though process. Inadvertant lateral collateral ligament injury is also a risk and can be longstanding.

In our experience, wrist extensor tendon lengthening in the distal forearm relieved pain in only about half of the cases in which this technique was tried. Friden and Lieber[11] studied the physiologic consequences of surgical lengthening of extensor carpi radialis brevis using intraoperative laser diffraction measurements of sarcomere length. They felt that their findings refuted weakening of muscle strength following the procedure despite a reduction of the resting tension of the muscle insertion. They advised further studies of joint mechanical properties during rehabilitation to better understand the adaptive phenomenon.

PARTIAL EPICONDYLECTOMY, DEBRIDEMENT, AND REPAIR

Our technique is a modification to a technique originally described by Avrum Froimson with the addition of drilling into the cancellous bone as described by Nirschl, Jobe, and others after the epicondylectomy.[34]

A pneumatic tourniquet is used to obtain the bloodless field essential to precise recognition and excision of damaged and inflamed tissue. Local infiltration should be used only after repairing all tissue planes and for this

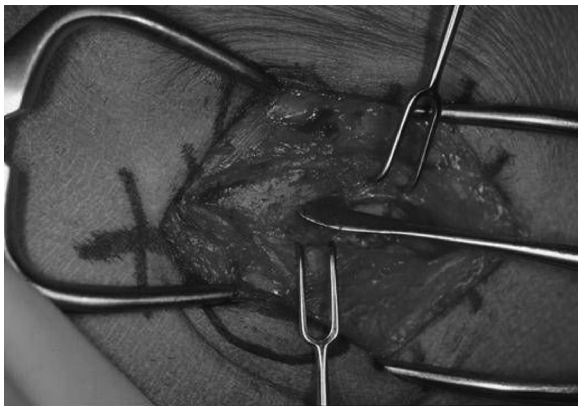

FIG. 2. Longitudinal incision across the lateral epicondyle utilizing a Freer Elevator to expose the ECRB (Copyright Kevin D. Plancher, M.D.).

reason we recommend axillary anesthesia or brief general anesthesia.

Lateral Epicondyle

In the operation for repair of the extensor origin, the patient is supine, with the affected arm placed on a padded hand table.

A longitudinal skin incision is made extending from 1 cm above the lateral humeral epicondyle to 4 cm distal to it to expose the common extensor origin. The deep antebrachial fascia is also incised longitudinally and retracted. The superficial fibers of origin of the extensor carpi radialis brevis may be intact and appear normal, they may be edematous and hyperemic, or they may be grossly disrupted or actually avulsed. In any case, the common extensor tendon is split by longitudinal incision and then sharply dissected off the lateral epicondyle approximately 0.8 cm both anteriorly and posteriorly

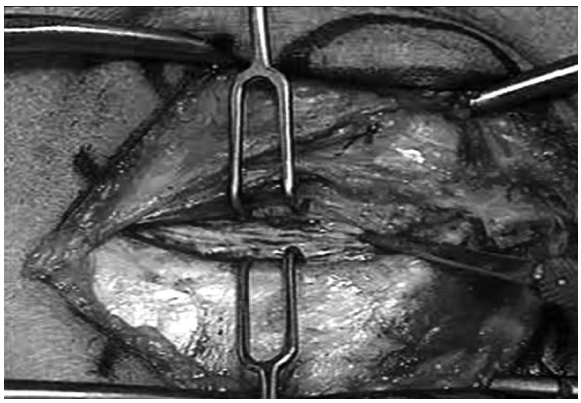

FIG. 3. The common extensor tendon is longitudinally split and dissected off the lateral epicondyle (Copyright Kevin D. Plancher, M.D.).

FIG. 4. Necrotic and torn tendon fibers and granulation tissue are excised (Copyright Kevin D. Plancher, M.D.).

(Figs. 2 and 3). The tear in the substance of the tendon or subaponeurotic space is identified. (The use of magnifying operating loupes is advised.) Necrotic and torn tendon fibers are excised along with any granulation tissue in the tendon or subaponeurotic space (Fig. 4). The lateral epicondyle is exposed after the necrotic tissue is excised (Fig. 5).

With a narrow osteotome, enough of the tip of the lateral epicondyle is excised to produce a raw cancellous bone surface and to permit approximation of the edges of the debrided extensor tendon over bone without tension (Figs. 6 and 7). The excised piece of epicondyle is usually 0.5-cm thick.

To stimulate neovascularization and fibrotendon regeneration of the resected area, one or two small holes are drilled into the cancellous bone with the use of a 0.62 K-wire.[34]

The elbow joint is not intentionally entered; however, while debriding the area, a small rent is sometimes

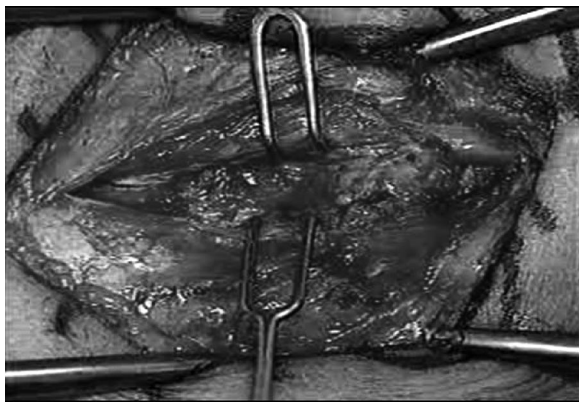

FIG. 5. Lateral epicondyle exposed after the necrotic ECRB origin is excised (Copyright Kevin D. Plancher, M.D.).

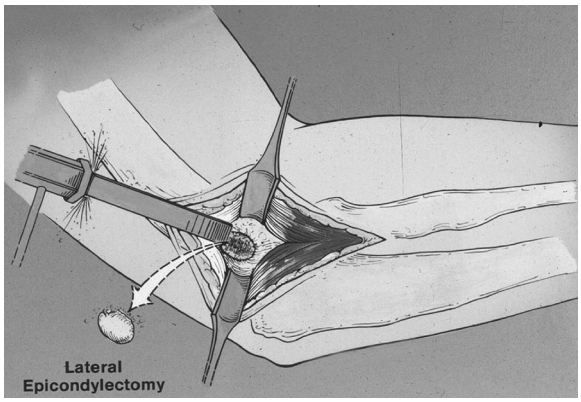

FIG. 6. Artistic rendition: the tip of the lateral epicondyle is removed with a saw (Copyright Kevin D. Plancher, M.D.).

FIG. 8. Closure of the common extensor tendon is closed (Copyright Kevin D. Plancher, M.D.).

encountered or created in the joint capsule. This can be used to inspect the capitellum and radial head if sufficiently large. Hypertrophic synovium or any synovial plicae or fold should be excised if encountered. If the joint was accidentally opened or found to be opened, it will seal with a proper closure using nonabsorbable sutures. Care is taken to avoid injury to the radial collateral ligament. If the radial collateral ligament is inadvertently cut during the release, the elbow will become unstable, demonstrating the findings of posterolateral instability with a new clicking or snapping experienced by the patient.

The operation is completed by closing the defect over the lateral epicondyle by approximating the edges of the common extensor tendon over the cut bone surface and suturing this tendon to adjacent soft tissue, such as the periosteum and triceps fascia margin (Figs. 8 and 9) if necessary to ensure complete closure with nonabsorbable, undyed braided nylon. Although the use of suture anchors has been occasionally suggested by others, the use of such foreign body devices in the lateral epicondyle is not recommended.

Postoperative Treatment

After subcuticular skin closure, a laterally reinforced posterior splint is applied extending from the axilla to the palmar crease with the elbow at a right angle the forearm in midposition, and the wrist in slight extension. After 2 weeks, the splint is removed to allow active elbow exercises without resistance. At the end of the first month, the patient is encouraged to regain grip strength by using a hand-held spring exerciser, an elastic or rubber device, or exercise putty alternatively the patient may attend hand therapy. At 8 weeks, resistive elbow and wrist flexion and extension exercises are done using dumbbell weights or other gym apparatus. By the end of 2 months, the patient should have regained adequate strength to resume sports or assembly line work with

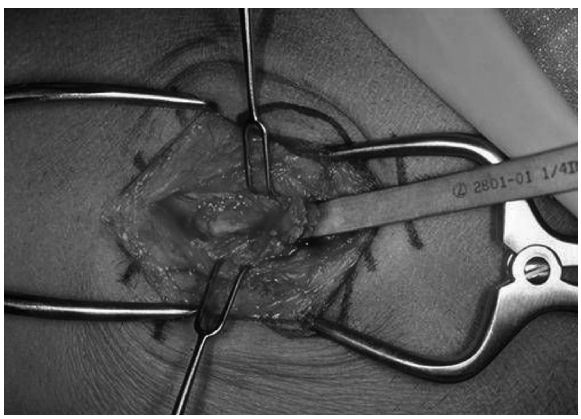

FIG. 7. The tip of the lateral epicondyle is removed with a saw (Copyright Kevin D. Plancher, M.D.).

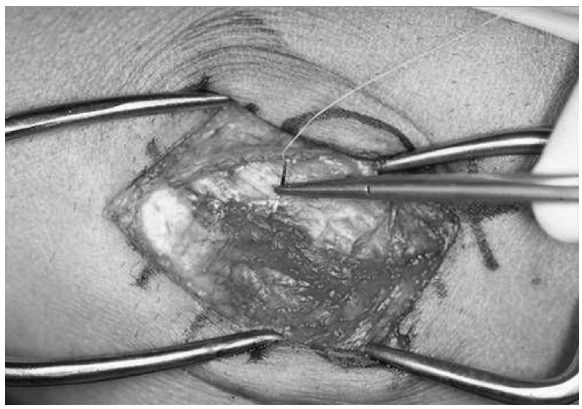

FIG. 9. The cut edges of the common extensor tendon are approximated over the cut bone surface to complete the repair (Copyright Kevin D. Plancher, M.D.).

little or no discomfort. A forearm support band[13] should be worn while working or playing for several months to help prevent recurrence of injury.

Patients with workers' compensation claims are not managed any differently from the weekend athlete or sedentary individual. Once healed, there is no increased risk in recurrence of problems after return to vigorous work. Change of work duties is not recommended.

RESULTS

In a retrospective review of the a Nirschl repair for lateral epicondylosis,[33] 38 elbows resistant to nonoperative treatment operated over a 10-year period were evaluated. A 4-part grading system was used to measure outcomes. An excellent result was given for complete satisfaction, no perceived loss of grip strength, and no pain. A good rating was recorded for patients who are completely satisfied, had no or little perceived loss of grip strength, and reported only occasional slight pain at the lateral epicondyle only after strenuous exercises. A fair result was given for the patients who were at least moderately satisfied, reported slight or moderate subjective loss of grip strength, and had discomfort at the lateral epicondyle after strenuous activity, but stated that the pain was more tolerable than it was preoperatively. A poor rating was given to any patient who was not satisfied or reported severe subjective loss of grip strength or had no change in the preoperative pain. Thirty-eight percent were rated as excellent, 41% as good, 21% were fair, and none were poor. Eighty-six percent of these patients were able to return to the regular work, sport, or hobby, including patients who perform repetitive activities working on industrial assembly lines. Fourteen percent reported some reduction in capacity. New rating systems are needed to be more objective and prospective studies need to be conducted to truly allow us to understand outcomes for this disease process.

We have used this procedure since 1993 in over 50 patients with no failures to date but a prospective study has no begun with an arthroscopic technique as the alternative modality.

ACKNOWLEDGMENTS

We would like to pay special consideration to Dr. Avrum I. Froimson for inspiring us to use his previous description of the open technique for the treatment of lateral epicondylitis. We would like to thank him for our ability to treat and care for our patients thanks to his writings and teachings.

REFERENCES

1. Baumgard SH, Schwartz DR. Percutaneous release of the epicondylar muscles for humeral epicondylitis. *Am J Sports Med* 1982; 10:233–236.
2. Bennett TB. Lateral and medial epicondylitis. *Hand Clin* 1994;10: 157–163.
3. Bosworth DM. The role of the orbicular ligament in tennis elbow. *J Bone Joint Surg* 1955;37A:527–533.
4. Bosworth DM. Surgical treatment of tennis elbow: a follow-up study. *J Bone Joint Surg* 1965;47A:l533–1536.
5. Boyd HB, McLeod AC. Tennis elbow. *J Bone Joint Surg* 1973; 55A:1183–1187.
6. Cabot A. Tennis elbow. A curable affliction. *Orthop Rev* 1987;16: 69–73.
7. Carroll RE, Jorgensen EC. Evaluation of the Garden procedure for lateral epicondylitis. *Clin Orthop.* 1968;60:20 1–204.
8. Coonrad RW, Hooper WR. Tennis elbow: its course, natural history, conservative and surgical management. *J Bone Joint Surg* 1973;55A:l177–1182.
9. Cyriax JH. The pathology and treatment of tennis elbow. *J Bone Joint Surg* 1936;18A:92l–940.
10. Doran A, Gresham GA, Rushton N, et al. Tennis elbow. A clinicopathologic study of 22 cases followed for 2 years. *Acta Orthop Scand* 1990;61:535–538.
11. Friden J, Lieber RL. Physiologic consequences of surgical lengthening of extensor carpi radialis brevis muscle-tendon junction for tennis elbow. *J Hand Surg* 1994;19A:269–274.
12. Friedlander HL, Reid RL, Cape RF. Tennis elbow. *Clin Orthop* 1967;51:109–116.
13. Froimson AI. Treatment of tennis elbow with forearm support band. *J Bone Joint Surg* 1971;53A:183–184.
14. Gabel GT, Morrey BF. Operative treatment of medial epicondylitis. Influence of concomitant ulnar neuropathy at the elbow. *J Bone Joint Surg* 1995;77A:1065–1069.
15. Garden RS. Tennis elbow. *J Bone Joint Surg* 1961;43B:100–l06.
16. Gardner RC. Tennis elbow: diagnosis, pathology and treatment. Nine severe cases treated by a new reconstructive operation. *Clin Orthop* 1970;72:248–253.
17. Goldie I. Epicondylitis lateralis humeri (epicondylitis or tennis elbow). *Acta Chir Scand (suppl)* 1964;339:1–119.
18. Heyse-Moore GH. Resistant tennis elbow. *J Hand Surg* 1984;9B: 64–66.
19. Hohi M. Epicondylitis-tennis elbow. *Clin Orthop* 1961;19:232–238.
20. Jalovaara P, Lindholm RV. Decompression of the posterior interosseous nerve for tennis elbow. *Arch Orthop Trauma Surg* 1989;108:243–245.
21. Jobe FW, Ciccotti MG. Lateral and medial epicondylitis of the elbow. *J Am Acad Orthop Surg* 1994;2:1–8.
22. Kaplan EB. Treatment of tennis elbow (epicondylitis) by denervation. *J Bone Joint Surg* 1959;41A:l47–151.
23. Kleinert JM, Mehta S. Radial nerve entrapment. *Orthop Clin North Am* 27:305–315, 1996.
24. Kurvers H, Verhaar J. The results of operative treatment of medial epicondylitis. *J Bone Joint Surg* 1995;77A:1374–1379.
25. Lister GD, Belsole RB, Kleinert HE. The radial tunnel syndrome. *J Hand Surg* 1979;4A:52–59.
26. Michele AA, Krueger FJ. Lateral epicondylitis of the elbow treated by fasciotomy. *Surgery* 1956;39:277–284.
27. Mills GP. The treatment of "tennis elbow." *BMJ* 1928;1:12–13.
28. Moss SH, Switzer HE. Radial tunnel syndrome: a spectrum of clinical presentations. *J Hand Surg* 1983;8:411–420.
29. Newey ML, Patterson MH. Pain relief following tennis elbow release. *J R Coll Surg Edinb* 1994;39:60–61.
30. Newman JH, Goodfellow JW. Fibrillation of head of radius as one cause of tennis elbow. *BMJ* 1975;2:328–330.
31. Nirschl RP. Tennis elbow. *Orthop Clin North Am* 1973;3:787–800.
32. Nirschl RP. The etiology and treatment of tennis elbow. *Sports Med* 1974;2:308–323.

33. Nirschl RP. Soft-tissue injuries about the elbow. *Clin Sports Med* 1986;5:637–652.
34. Nirschl RP, Pettrofle FA. Tennis elbow: the surgical treatment of lateral epicondylitis. *Bone Joint Surg* 1979;61A:832–839.
35. Ollivierre CO, Nirschl RP, Pettrone FA. Resection and repair for medial tennis elbow. A prospective analysis. *Am Sports Med* 1995;23:214–221.
36. Osgood RB. Radioh umeral bursitis, epicondylitis, epicondylalgia (tennis elbow): a personal experience. *Arch Surg* 1922;4:420–433.
37. Regan W, Wold LE, Coonrad R, Morrey BF. Microscopic histopathology of chronic refractory lateral epicondylitis. *Am Sports Med* 1992;20:746–749.
38. Roles NC, Maudsley RH. Radial tunnel syndrome: resistant tennis elbow as a nerve entrapment. *Bone Joint Surg* 1972;54B:499508.
39. Savastano AA, Kamioneck S, Knowles K, et al. Treatment of resistant tennis elbow: a combined surgical procedure. *Int Surg* 1972;57:470–474.
40. Spencer GE, Herndofl CR. Surgical treatment of epicondylitis. *J Bone Joint Surg* 1953;35A:421–424.
41. Trethwail WH. Tennis elbow. *BMJ* 1929;2:1218–1219.
42. van Rossuin J, Buruma OJ, Kamphuisen HA, et al. Tennis elbow: a radial tunnel syndrome? *J Bone Joint Surg* 1978;60B:197–198.
43. Verhaar J, Walenkamp G, Kester A, et al. Lateral extensor release for tennis elbow. A prospective long-term follow-up study. *J Bone Joint Surg* 1993;75A:l034–l043.
44. Wadsworth TG. Tennis elbow: conservative, surgical, and manipulative treatment. *BMJ* 1987;294:621–624.
45. Werner CO. Lateral elbow pain and posterior interosseous nerve entrapment. *Acta Orthop Scand (suppl)* 1979;174:1–62.
46. Wittenberg RH, Schall S, Muhr G. Surgical treatment of persistent elbow epicondylitis. *Clin Orthop* 1992;278:73–80.
47. Yerger B, Turner T. Percutaneous extensor tenotomy for chronic tennis elbow: an office procedure. *Orthopedics* 1985;8:1261–1263.