

Arthroscopic Repair of Radial-Sided Triangular Fibrocartilage Complex Lesions

KEVIN D. PLANCHER, M.D., M.S.
*Hand and Sports Medicine Orthopaedic Associates,
Stamford, Connecticut, U.S.A.*

KENNETH J. FABER, M.D., F.R.C.S.(C)
*Hand and Upper Limb Center,
St. Joseph's Health Center,
London, Ontario, Canada*

■ HISTORICAL PERSPECTIVE

Dislocation of the distal radial ulnar joint was described as early as 1791 (8). Since that time, the function of the structures at the distal radial ulnar joint have been reported extensively (5,7,11,18,27,37,41). A major structure, the triangular fibrocartilage complex (TFCC), functions as a cushion between the distal end of the ulna and the radial ulnocarpal joint. The TFCC is a ligamentous connection between the distal radius and the ulnar side of the carpus. Loss of the TFCC support may lead to subluxation and dislocation of the distal radial ulnar joint. Although previous reports have recommended a complete excision of the TFCC (13), we do not recommend this as an initial treatment for the painful distal radial ulnar joint. Excision of the TFCC over time leads to an increase in ulnar lunate abutment and erosion of the cartilage, with increasing wrist pain.

Arthroscopic repair of an ulnar-sided TFCC perforation has been described in several reports (5,39). Unanswered questions remain as to whether radial-sided tears of the TFCC heal after repair. Bednar et al. (2) showed that the majority of blood supply was found along the peripheral edge of the TFCC and suggested that the radial edge would therefore not heal if repaired. However, we, like Cooney et al. and others, believe otherwise (5,6). When the ulnar edge of the distal radius has been burred to a bleeding cancellous bone bed, we have been able to repair the TFCC arthroscopically back to its anatomic position. The X-ray of such a structure changes from an open distal radial ulna joint to a normal closed position on a zero-rotation posteroanterior (PA) radiograph at a 2-year follow-up (Fig. 1A-D). Cooney et al. showed with postrepair magnetic resonance imaging (MRI) that heal-

ing can occur in patients with a radial-sided TFCC tear performed in an open fashion (5).

The triangular fibrocartilage complex (TFCC) has recently been recognized as a cause of ulnar-sided wrist pain. With the development of wrist arthroscopy and improved wrist imaging, tears of this structure have been more readily identified (4,10,14,15,17,28,30-32,34).

The term *TFCC* was coined by Palmer and Werner in 1981 (26) and is a vital structure with attachments to the ulna, radius, and ulnar carpus. The TFCC has been divided into the triangular fibrocartilage, the articular disk, the dorsal and palmar ligamentous attachments, the meniscus homologue, and the extensor carpi ulnaris subsheath (Fig. 2A, B) (23).

The TFCC has several functions including load transmission for the distal radial ulnar joint and ulnar carpus stabilization (26). The load transferred to the TFCC is dependent on forearm rotation. Biomechanical studies have shown that the TFCC distributes up to 20% of the load across the ulnar wrist (23). In supination the ulna assumes a relative shorter position, and in pronation the ulna assumes a relative longer position (36). The dorsal and volar radial ulnar ligaments represent thickening within the TFCC, which are the primary stabilizers of the distal radial ulnar joint (28). Additional reflections from the TFCC distally to the ulnar carpus assists in stabilizing the carpus. Injection studies of the TFCC have demonstrated vascularity of the peripheral 20% of attachments and the dorsal and radial attachments to the radius (2,23). However, articular disk attachments to the sigmoid notch of the radius are thought to be avascular (2).

TFCC tears have been classified as acute or chronic (Table 1) (22). Acute tears are subclassified based on the location of pathology, and chronic tears are subclassified based on the extent of disease and the presence of arthritis. Ulnar positive variance has been associated with the presence of a TFCC tear (25).

Address correspondence and reprint requests to Dr. Kevin D. Plancher, Hand and Sports Medicine Orthopaedic Associates, 1275 Summer Street, Suite 102, Stamford, CT 06905, U.S.A.

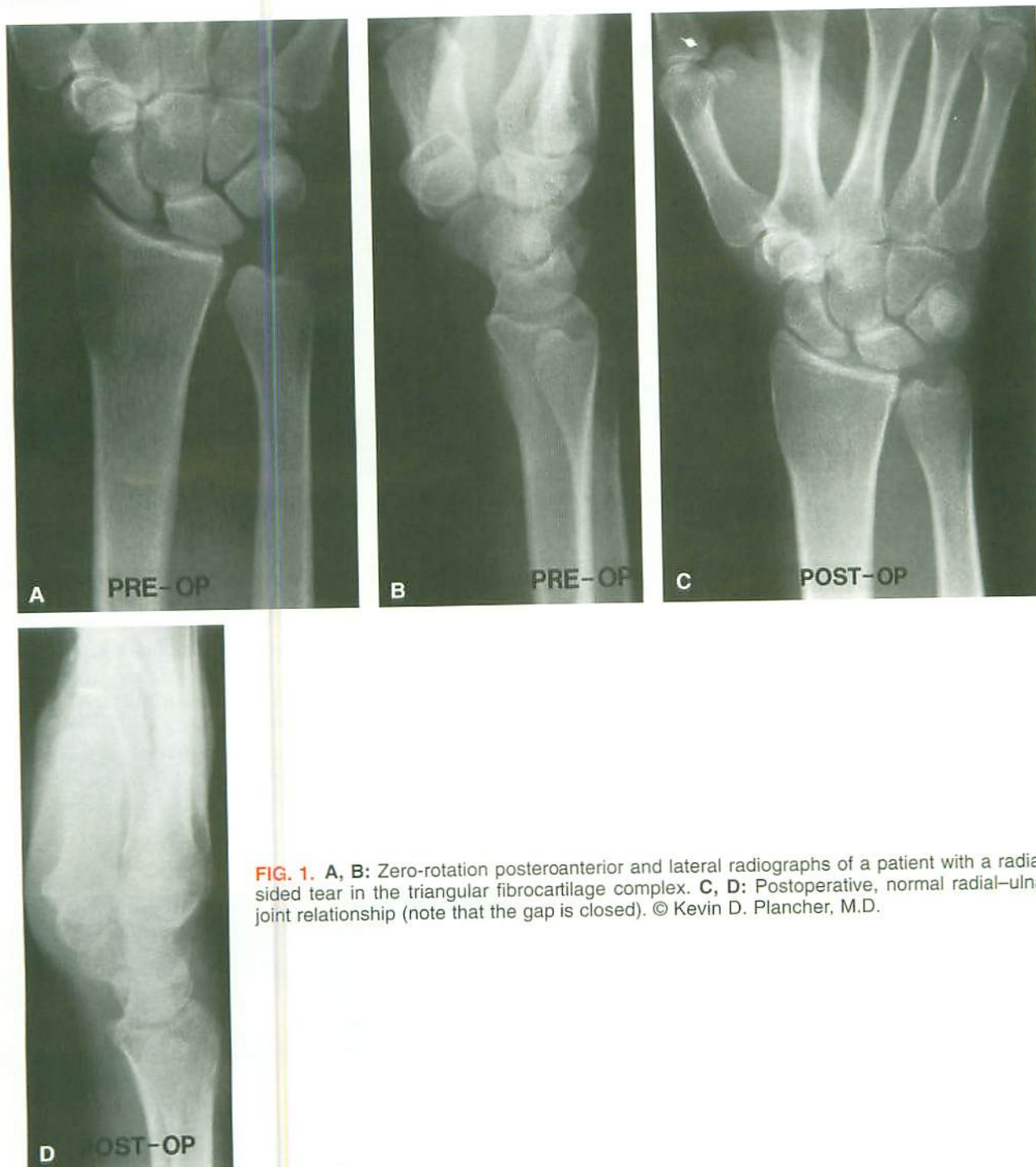

FIG. 1. A, B: Zero-rotation posteroanterior and lateral radiographs of a patient with a radial-sided tear in the triangular fibrocartilage complex. C, D: Postoperative, normal radial-ulnar joint relationship (note that the gap is closed). © Kevin D. Plancher, M.D.

■ DIAGNOSIS AND TREATMENT OF TFCC TEARS

The typical mechanism resulting in an injury to the TFCC involves an axial load with concomitant forearm rotation. To exclude other common causes of wrist pain such as arthritis and carpal instability, a detailed history

and clinical examination should be performed on all patients presenting with ulnar-sided wrist pain (24). The patient often describes a painful clicking and catching sensation along the ulnar aspect of the wrist, particularly with forearm rotation or ulnar deviation. The patient may also present with loss of forearm rotation and wrist motion. The clinical examination demonstrates reproducible

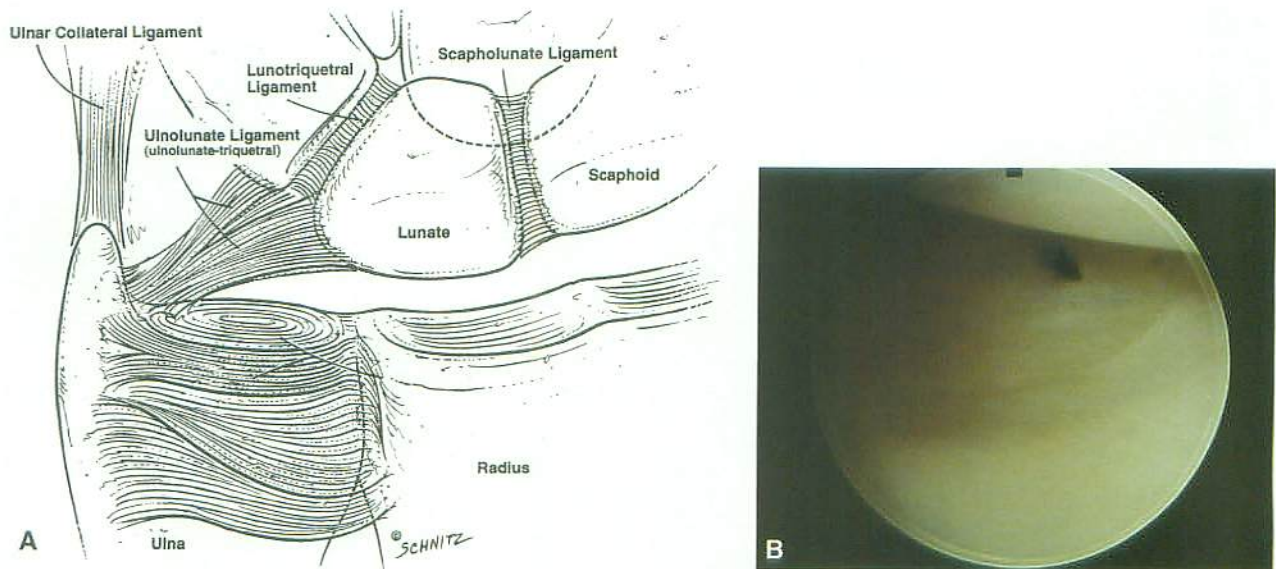


FIG. 2. A: Artist's rendering of normal triangular fibrocartilage complex (TFCC) anatomy. B: Arthroscopic view of normal TFCC anatomy. © Kevin D. Plancher, M.D.

well-localized tenderness over the TFCC either dorsally or ulnarly. Forced ulnar deviation can elicit pain and crepitus palpable during forearm rotation, thereby assisting in the diagnosis of TFCC perforation.

All patients should be evaluated with a zero-rotation PA and lateral plain radiographs of the wrist before undertaking any treatment regime. The discussion of indications for MRI and arthrography are beyond the scope of this paper, but these can be useful adjuncts in the diagnosis of TFCC tears/perforations (8,24).

The nonoperative treatment for TFCC tears include immobilization, physical therapy, and local steroid injections. Nonoperative treatment is recommended for 3 months. If symptoms improve, then a nonoperative course continues with occupational hand therapy. If the symp-

toms are unchanged or worsen, consideration should be given to surgical intervention. Operative interventions include ulnar shortening, hemiresection and interposition arthroplasty, debridement of the TFCC, and, more recently, operative repair (1,5,6,9,12,14,16,20,21,27).

Debridement of the TFCC tears is a well-recognized method of treatment. This can be performed by using an open arthrotomy or arthroscopically. Debridement removes unstable flaps of the TFCC that are avascular and

TABLE 1. Classification of triangular fibrocartilage complex lesions (22)

Traumatic lesions	
	Central rupture
	Ulnar avulsion
	Distal avulsion
	Radial avulsion
Degenerative lesions	
	Superficial
	Degenerative tear with chondral changes on the lunate or ulna
	Degenerative perforation with chondral lesion of the lunate or ulna
	Degenerative perforation with chondral lesion of the lunate or ulna and lunotriquetral instability
	Degenerative perforation with lunotriquetral instability and ulnocarpal arthritis

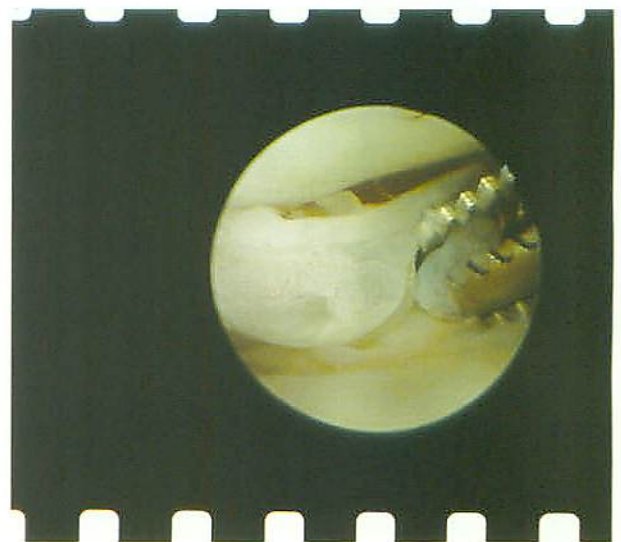

FIG. 3. Intraarticular wrist debridement of a flap of tissue over the triangular fibrocartilage complex. © Kevin D. Plancher, M.D.

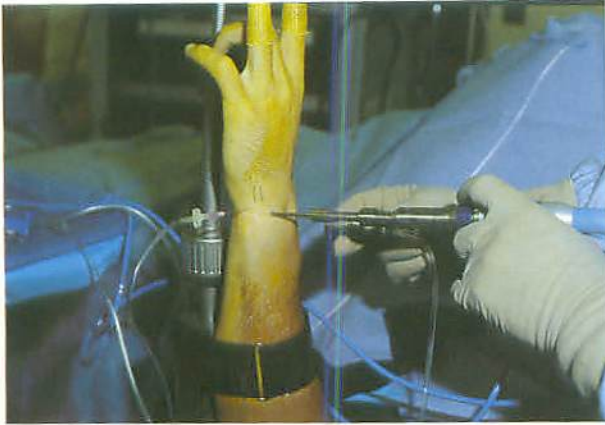


FIG. 4. Arthroscopic set-up of the right wrist using a wrist traction tower. © Kevin D. Plancher, M.D.

have no intrinsic ability to heal. Most chronic degenerative TFCC tears can be treated with this technique (Fig. 3).

An ulnar shortening osteotomy is performed to unload the ulnocarpal joint (3). This procedure is recommended if the TFCC tear is associated with an ulnar positive variance (40). The hemiresection interposition arthroplasty is also intended to unload the ulnocarpal joint without disrupting the TFCC (19). This procedure is recommended if distal radial ulnar joint arthrosis is present.

■ OPEN VERSUS ARTHROSCOPIC REPAIR

TFCC repair can be undertaken through open or arthroscopic techniques. The open technique involves a dorsal exposure of the distal radial ulnar joint through the fifth and sixth extensor compartments (5,12). The capsule is then incised to expose the TFCC. The tear in the TFCC can be directly visualized and suture repair undertaken.

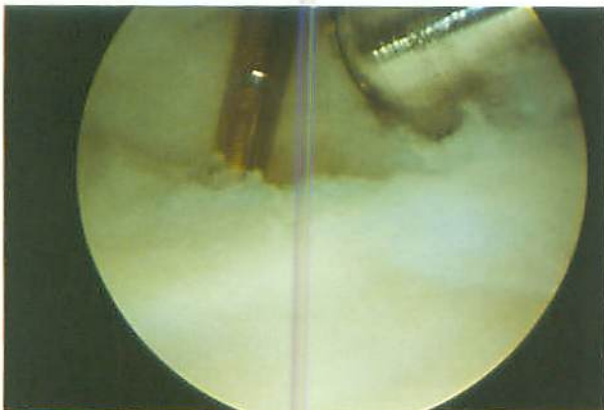


FIG. 5. Radial avulsion of the triangular fibrocartilage complex. © Kevin D. Plancher, M.D.

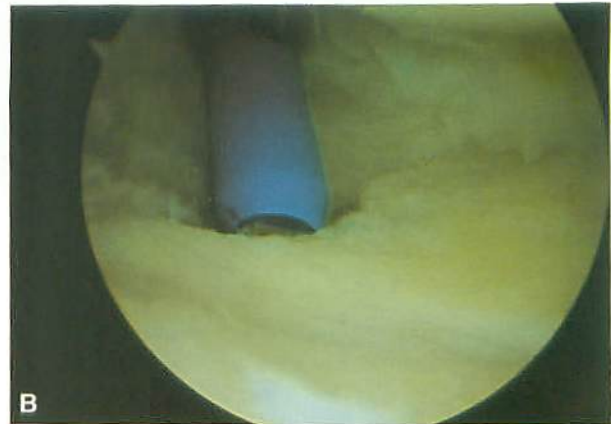
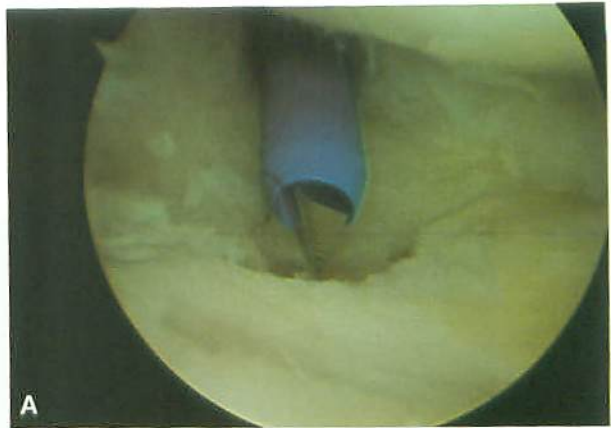


FIG. 6. A, B: Drill guide placed against the ulnar side of the radius and through the triangular fibrocartilage complex in preparation to drill holes. © Kevin D. Plancher, M.D.

These techniques were initially described for capsular detachments of the volar, ulnar, or dorsal portions of the TFCC. Specialized instruments have been developed that allow for arthroscopic repair of peripheral capsular detachments (6,9,34,39,42,43) with better visualization, in our opinion.

In the past, attempts at repair of radial-sided TFCC tears have not been undertaken because of equipment needs and the assumption that this site is avascular and without the potential to heal (2,29). Injection studies evaluating the vasculature of the TFCC, however, have demonstrated that the dorsal and volar radial ulnar ligaments are portions of the TFCC that are vascularized and thus have the theoretical potential to heal.

■ DESCRIPTION OF PROCEDURE (TABLE 2)

Standard wrist arthroscopy is performed with the extremity suspended by finger traps with 5–15 lbs. of counter traction. A wrist traction tower may be used. An

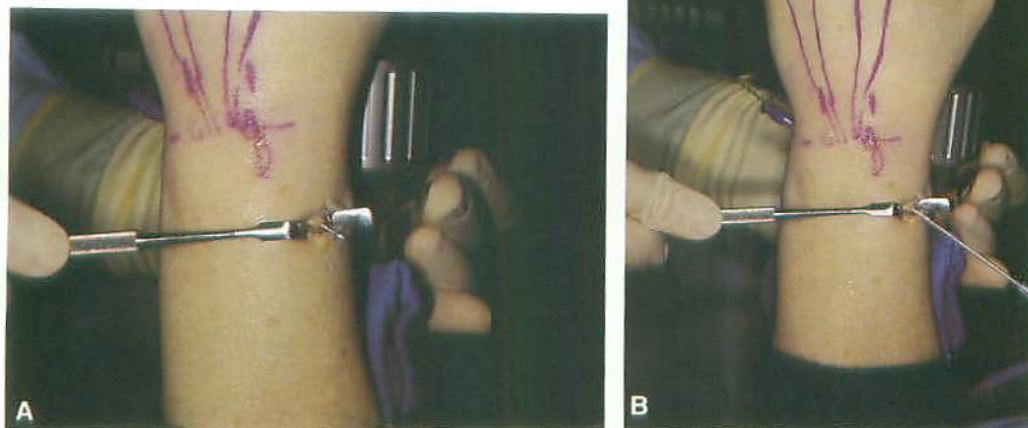


FIG. 7. A, B: Longitudinal incision with Kirschner wire protruding, coming from the ulnar side of the radius. © Kevin D. Plancher, M.D.

upper arm tourniquet is applied but is not initially inflated. Radial carpal portals are established between the 3-4 interval and the 6 R or 6 U intervals. The 3-4 portal is used for viewing, and the 6 R/6 U portal is used for instrumentation (Fig. 4). After completion of the diagnostic arthroscopy, a small-diameter bur is used to debride and decorticate the radial site of TFCC detachments (Fig. 5). Once a rough and bleeding surface has been established along the dorsal or volar aspect of the radiosigmoid notch, a suture passer is used to place sutures through the torn free edge of the TFCC. The suture ends

are retrieved through the 6 R/6 U portal. Alternatively, a drill guide may be used to place a meniscal needle from the ulnar to the radial side of the wrist by using a soft tissue sleeve (Fig. 6A, B) (33,38).

A 1–1.5-cm longitudinal incision is placed over the interval between the second and third extensor compartments. Using blunt dissection, the dorsal cortex of the distal radius is identified. Identification of the Kirschner wire and protection of the superficial radial nerve is performed (Fig. 7A, B). A 2-OPDS suture is passed with the use of a suture passer (Hewson) and is tied with a mul-

TABLE 2. Surgical technique for radial side TFCC repair

1. Arthroscopic evaluation of the tear
2. Debridement of the tear and the sigmoid notch with a motorized bur
3. Passage of a 2-0 suture through the free edge of the TFCC tear or use of a prethreaded meniscal needle
4. Exposure of the 2-3 interval and seating of the targeting drill guide or drilling freehand

If the targeting drill guide is used

5. Two converging 2-mm holes drilled with a 2-mm-diameter bit; a 5-mm bone bridge is left between each hole
6. Retrieval of the sutures using a Hewson suture passer

For all techniques

7. Assessment of forearm rotation that most appropriately reduces the TFCC tear
8. Tying of the suture limbs over the bone bridge
9. Arthroscopic evaluation of TFCC stability

TFCC, triangular fibrocartilage complex.

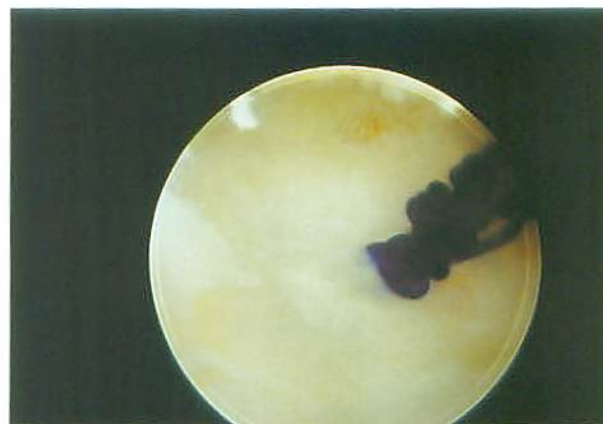

FIG. 8. Mulberry knot of 2 OPDS seen in the joint with repaired radial-sided tear of the triangular fibrocartilage complex. © Kevin D. Plancher, M.D.

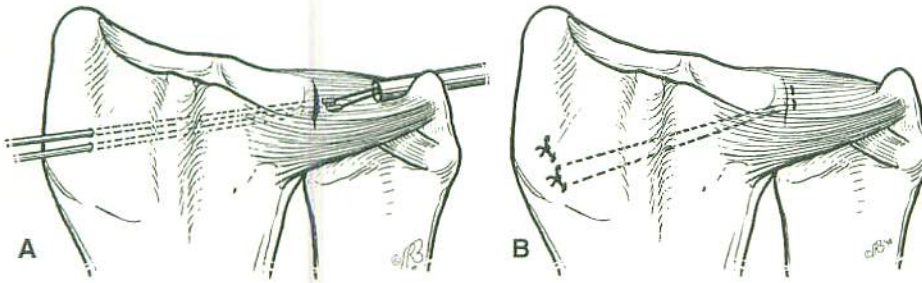


FIG. 9. A: Sutures placed in the triangular fibrocartilage complex through drill holes with a prethreaded meniscal needle. B: Suture tied over a bony bridge between the second and third extensor compartments. © Kevin D. Plancher, M.D.

berry knot drawn into the joint to suture the radial-sided tear (Fig. 8). A suture is then tied on the dorsal cortex of the radius. Alternatively, prethreaded meniscal needles may be used to tie a horizontal mattress suture (Fig. 9A, B) (33,38).

An alternative placement of the Kirschner wires by free hand can be done by using a targeting drill guide placed into the radiocarpal joint through the 6 R/6 U portal, with the barrel of the guide seated on the radius between the second and third extensor compartments (Fig. 10). Confirmation of drill guide placement is made arthroscopically and fluoroscopically. After the drill guide has been seated, a 2-mm drill hole is established. Care is taken to avoid the articular surface of the lunate facet of the distal radius. A second drill hole is offset from the first drill hole by 5 mm. The second drill hole converges to the same site within the sigmoid notch of the radius. A Hewson suture passer is then advanced through the drill hole and used to retrieve one suture limb that had been previously placed within the TFCC. The Hewson passer is then used to retrieve the second suture limb through the second drill hole. The TFCC is then visualized, and the forearm position that most accurately

reduces the TFCC is determined while tension is applied to the suture. The sutures are tied over the bony bridge, between the second and third extensor compartments, with the forearm in this position (Fig. 9B). Up to three sutures can be passed through each drill hole.

Postoperatively, the wrist and forearm are immobilized in a Muenster cast or with pinning of the distal ulna to the distal radius. These two methods control forearm rotation. The position of immobilization is determined intraoperatively and is based on the position that most appropriately reduces the TFCC. After 4–6 weeks, the forearm immobilization is exchanged for a standard forearm cast for an additional 4 weeks. After immobilization, physical therapy is initiated, with active assisted range of motion, passive range of motion, and gentle strengthening exercises.

Additional, innovative techniques have also been recently described. Fellingner et al. described the technique for repair of radial avulsion of the TFCC with a T-fix suture anchoring device (9). With their technique, a Kirschner wire is passed from the sigmoid notch through the radial cortex of the distal radius. The Kirschner wire is then overreamed to 2.5 mm, followed by insertion of

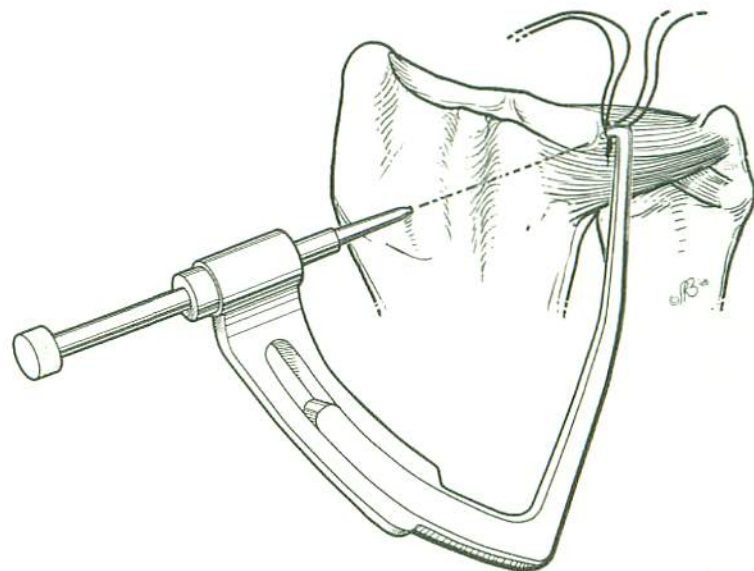


FIG. 10. Placement of a targeting drill guide through the 6 R/6 U portal and 2-3 interval. © Kevin D. Plancher, M.D.

the suture anchor. The suture is then secured to the periosteum of the radius. With our technique, two drills holes are used, and the sutures are tied over a bony bridge or one suture is tied as a mulberry knot. We believe our technique provides a more secure fixation and accurate placement of sutures into the periosteum of the radius (two drill holes).

■ COMPLICATIONS

Complications of TFCC repair include injury to the dorsal sensory branch of the ulnar nerve, the dorsal sensory branch of the radial nerve, the radial artery, extensor tendons, and iatrogenic chondromalacia. Meticulous technique and attention to detail can prevent most of these complications. When a transverse branch of the dorsal sensory branch of the ulnar nerve is present, persistent numbness may occur; therefore, all patients must be alerted to the possible presence of this branch of the dorsal ulna sensory nerve (12).

■ SUMMARY

The development of wrist arthroscopy and MRI has allowed for increased recognition of tears of the TFCC as a cause of ulnar-sided wrist pain. The proliferation of arthroscopic instrumentation has allowed for successful arthroscopic repair of these injuries.

Open techniques have also been described for repair of the TFCC. Satisfactory results have been reported with open techniques. The arthroscopic approach minimizes the amount of dissection required for repair of the TFCC and has the theoretical advantage of reducing subsequent scar formation and wrist stiffness. These arthroscopic techniques are technically difficult and should be performed by surgeons experienced in wrist arthroscopy.

■ REFERENCES

- 1) Adams BD. Partial excision of the triangular fibrocartilage complex articular disc: a biomechanical study. *J Hand Surg* 1993;18A:334-40.
- 2) Bednar MS, Arnoczky SP, Weiland AJ. The microvasculature of the triangular fibrocartilage complex: its clinical significance. *J Hand Surg* 1991;16A:1101-5.
- 3) Boulas HJ, Milek NA. Ulnar shortening for tears of the triangular fibrocartilage complex. *J Hand Surg* 1990;15A:415-20.
- 4) Cerofolini E, Lechetti R, Pederzini L, et al. Magnetic resonance evaluation of triangular fibrocartilage complex tears in the wrist: comparison with arthrography and arthroscopy. *J Comput Assist Tomogr* 1990;14:963-7.
- 5) Cooney WP, Linscheid RL, Dobyns JH. Triangular fibrocartilage tears. *J Hand Surg* 1994;19A:143-54.
- 6) Corso SJ, Savoie FH, Geissler WB, Whipple TL, Jimenez W, Jenkins N. Arthroscopic repair of peripheral avulsions of the triangular fibrocartilage complex of the wrist: a multicentre study. *Arthroscopy* 1997;13:78-84.
- 7) Dameron TB. Traumatic dislocation of the distal radial ulnar joint. *Clin Orthop* 1972;83:55-63.
- 8) DeSault M. Extrait d'un memoire de M. DeSault sur la luxation de l'extremite inferieure du radius. *J Chir* 1791;1:78-87.
- 9) Fellinger M, Peicha G, Seibert J, Grechenig W. Radial avulsion of the triangular fibrocartilage complex in acute wrist trauma: a new technique for arthroscopic repair [technical note]. *Arthroscopy* 1997;13:370-4.
- 10) Golimbu CN, Firooznia H, Melone CP, Rafii M, Weinreb J, Leber C. Tears of the triangular fibrocartilage of the wrist: magnetic resonance imaging. *Radiology* 1989;173:731-3.
- 11) Hamlin C. Traumatic disruption of the distal radial ulnar joint. *Am J Sports Med* 1977;5:93-7.
- 12) Hermansdorfer JD, Kleinman WB. Management of chronic peripheral tears of the triangular fibrocartilage complex. *J Hand Surg* 1991;16A:340-6.
- 13) Imbriglia JE, Boland DS. Tears of the articular disk of the TFCC: results of excision of the articular disk. *J Hand Surg*. 1983;8:620.
- 14) Kang HS, Kindynis P, Brahme SK, et al. Triangular fibrocartilage and intercarpal ligaments of the wrist: magnetic resonance imaging. *Radiology* 1991;181:401-4.
- 15) Levinsohn EM, Rosen ID, Palmer AK. Wrist arthroscopy: value of the three compartment injection method. *Radiology* 1991;179:231-9.
- 16) Menon J, Wood BE, Schoene HR, Frykman GK, Hohl JC, Bestard EA. Isolated tears of the triangular fibrocartilage of the wrist: results of partial excision. *J Hand Surg* 1984;9A:527-30.
- 17) Metz VM, Schratte M, Dock WI, et al. Age associated changes of the triangular fibrocartilage of the wrist: evaluation of the diagnostic performance of magnetic resonance imaging. *Radiology* 1992;184:217-20.
- 18) Mikic ZDJ. Age changes in the triangular fibrocartilage of the wrist joint. *J Anat* 1978;126:367-84.
- 19) Minami A, Kaneda K, Itoga H. Hemiresection—interposition arthroplasty of the distal radioulnar joint associated with repair of the triangular fibrocartilage complex tears. *J Hand Surg* 1991;16A:1120-5.
- 20) Osterman AL. Arthroscopic debridement of triangular fibrocartilage complex tears. *Arthroscopy* 1990;6:120-4.
- 21) Osterman AL, Terrill RG. Arthroscopic treatment of triangular fibrocartilage complex lesions. *Hand Clinics* 1991;7:277-81.
- 22) Palmer AK. Triangular fibrocartilage complex lesions: a classification. *J Hand Surg* 1989;14A:594-605.
- 23) Palmer AK. Triangular fibrocartilage disorders: injury, patterns, and treatment. *Arthroscopy* 1990;6:125-32.
- 24) Palmer AK. Partial excision of the triangular fibrocartilage complex. In: Gelberman RH, ed. *Master techniques in orthopaedic surgery: the wrist*. New York: Raven Press, 1994:207-18.

- 25) Palmer AK, Glisson RR, Werner FW. Relationship between ulnar variance and triangular fibrocartilage complex thickness. *J Hand Surg* 1984;9A:681-3.
- 26) Palmer AK, Werner FW. The triangular fibrocartilage complex of the wrist—atomy and function. *J Hand Surg* 1981;6A:153-62.
- 27) Palmer AK, Werner FW, Glisson RR, Murphy DJ. Partial excision of the triangular fibrocartilage complex. *J Hand Surg* 1988;13A:391-4.
- 28) Pederzini L, Luchetti R, Soragni O, et al. Evaluation of the triangular fibrocartilage complex tears by arthroscopy, arthrography, and magnetic resonance imaging. *Arthroscopy* 1992;8:191-7.
- 29) Phiro-Pathi RG, Ferlic DC, Clayton ML, McClure DC. Arterial anatomy of the triangular fibrocartilage complex of the wrist and its surgical significance. *J Hand Surg* 1986;11A:258-63.
- 30) Potter HG, Asnis-Ernberg L, Weiland AJ, Hotchkiss RN, Petersen NGE, McCormack RR. The utility of high-resolution magnetic resonance imaging in the evaluation of the triangular fibrocartilage complex of the wrist. *J Bone Joint Surg* 1997;79A:1675-84.
- 31) Roth JH, Haddad RG. Radiocarpal arthroscopy and arthrography in the diagnosis of ulnar wrist pain. *Arthroscopy* 1986;2:234-43.
- 32) Roth JR, Poehling GT, Whipple TL. Arthroscopic surgery of the wrist. *Instruct Course Lect* 1988;37:183-94.
- 33) Sagerman SD, Short W. Arthroscopic repair of radial-sided triangular fibrocartilage complex tears. *Arthroscopy* 1996;12:339-42.
- 34) Schweitzer ME, Brahme SK, Hoddler J, et al. Chronic wrist pain: spin-echo image and short tau inversion recovery magnetic resonance imaging and conventional magnetic resonance image arthrography. *Radiology* 1992;182:205-11.
- 35) Skie MC, Mekhail MD, Deitrich DR, Ebraheim NE. Operative technique for inside-out repair of the triangular fibrocartilage complex. *J Hand Surg* 1997;22A:814-7.
- 36) Steyers CM, Blair WS. Measuring ulnar variance: a comparison of techniques. *J Hand Surg* 1989;14A:607-12.
- 37) Taleisnik J. The ligaments of the wrist. *J Hand Surg* 1976;1:110-8.
- 38) Trumble TE, Gilbert M, Vedder N. Arthroscopic repair of the triangular fibrocartilage complex. *Arthroscopy* 1996;12:588-97.
- 39) Trumble TE, Gilbert M, Vedder N. Isolated tears of the triangular fibrocartilage complex: management by early arthroscopic repair. *J Hand Surg* 1997;22A:57-65.
- 40) Trumble TE, Gilbert M, Vedder N. Ulnar shortening combined with arthroscopic repairs in temperature delayed management of triangular fibrocartilage complex tears. *J Hand Surg* 1997;22A:807-13.
- 41) Weigh K, Sira E. The triangular fibrocartilage of the wrist joint in reconstruction. *Surg Traumatol* 1969;11:139-53.
- 42) Whipple TL, Geissler WB. Arthroscopic management of wrist triangular fibrocartilage complex injuries in athletes. *Orthopaedics* 1993;16:1061-7.
- 43) Zachee B, DeSmit L, Fabry G. Arthroscopic suturing of triangular fibrocartilage complex lesions: a technical note. *Arthroscopy* 1993;9:242-3.