

RECALCITRANT CARPAL TUNNEL

The Hypothenar Fat Pad Flap

Kevin D. Plancher, MD, MS, Richard S. Idler, MD,
Gary M. Lourie, MD, and James W. Strickland, MD

Idiopathic carpal tunnel syndrome has become one of the most common peripheral neuropathies in the upper extremity,²³ since its first description by Sir James Paget in 1854.¹⁹ Although Marie and Foix, in 1913,¹⁷ recommended decompression of the median nerve by sectioning the transverse carpal ligament, it was not until 1930 that the first surgical decompression for this entity was performed by Sir James Learmonth.¹¹ Contributions by George Phalen, in his report to the American Society for Surgery of the Hand in 1965, detailing his 17 years' experience,²¹ added a lot of information to the evaluation and management of this entity. As the incidence of this surgical procedure increases, however, the most common complication following open carpal tunnel surgery plaguing surgeons is a failure to relieve the patient's symptoms.

The incidence of failure in open carpal tunnel decompression varies from 10% to 25%.^{1, 4, 9, 10, 15, 21} The most commonly cited causes for recalcitrant carpal tunnel syndrome or failure of open decompression include incomplete release of the transverse carpal ligament or antebrachial fascia, recurrent tenosynovitis, reformation of the flexor retinaculum, postoperative adhesions, and intraneural fascicular scarring.^{9, 14, 15, 16, 28, 32} Persistent proximal pain migration as well as palmar hypersensitivity have been reported infrequently but, when present, usually are disabling sequelae of open carpal tunnel decompression.^{4, 15} Although some have stated that the most common pathologic finding at re-exploration of the median nerve

was tenosynovitis or a fibrous proliferation within the carpal tunnel compressing the nerve,¹⁰ we believe otherwise. We believe, as others have written, that recurrence often is the result of a median nerve that is fixed toward the volar surface and radial side of the carpal canal.⁵ It is this adherence of the nerve to the undersurface of the transected transverse carpal ligament that results in traction dysesthesias with any wrist motion.⁵

Conservative treatment for recalcitrant carpal tunnel syndrome may provide immediate relief of symptoms but usually fails to give all patients a long-term benefit because of the inability to reverse the cause of the nerve compression. Although there is controversy in the literature,¹⁶ we, like the majority of surgeons, believe that repeat decompression and neurolysis or even more proximal surgical intervention for the patients with persistent or recurrent symptoms often are disappointing.^{10, 26, 32} It is unfortunate that a few patients must undergo multiple explorations with the median nerve extricated from the transverse carpal ligament during each procedure, only to have the symptoms return as the nerve adheres again.

In an attempt to address this complex problem, several surgical procedures have been described, all of which attempt to alleviate residual intraneural fascicular scarring and adherence of the median nerve to the radial leaf of the transverse carpal ligament.^{5, 12, 13, 18, 24, 30, 31, 32} All of these procedures provide coverage of the neurolysed median nerve and an attempt to provide an improved tissue environment that hopefully will discourage addi-

From the Albert Einstein College of Medicine, Montefiore Medical Center, Bronx, New York (KDP); Steadman Hawkins Clinic, Vail, Colorado (KDP); Indiana University School of Medicine and The Indiana Hand Center, Indianapolis, Indiana (JWS and RSI); and Department of Orthopaedics, Emory University; and The Hand Treatment Center, Atlanta, Georgia (GML)

tional scarring and adherence of the nerve to the transverse carpal ligament. Many of these procedures are technically demanding, use muscles often of insufficient size, are fraught with complications, and may require the sacrifice of normal, functioning tissue and muscle.^{3, 28}

The hypothenar fat pad flap mobilizes fat as a pedicled flap from the hypothenar eminence. The flap is interposed between the neurolysed median nerve and the radial leaf of the transverse carpal ligament. The fat pad prevents re-adherence and returns a gliding bed for the median nerve. This procedure has been used since 1987 by the senior author (JWS) and modified from its original description by Cramer.³

ANATOMIC DISSECTIONS OF THE HYPOTHENAR FAT PAD FLAP

The hypothenar muscles consistently are covered with a generous layer of adipose tissue of width and thickness sufficient to provide coverage of the carpal tunnel. A latex arterial injection was performed on a fresh frozen cadaver upper extremity to evaluate whether this adipose tissue could be mobilized without compromising its vascularity and to investigate the blood supply of the hypothenar fat pad flap. Dissection of the hypothenar fat pad demonstrated arterial branches to the fat pad arising directly from the ulnar side of the ulnar artery in Guyon's canal and, more distally, from branches of the ulnar artery to the small finger and fourth web space (Fig. 1). These transverse branches occurred approximately one every centimeter, beginning at the distal wrist flexion crease. There were additional arterial branches to the fat pad arising from arterial branches to the hypothenar muscles and palmaris brevis muscle. The skin overlying the hypothenar fat pad revealed an additional plexus of arteries running through the superficial adipose tissue. Critical to our observations in dissecting the fat pad was that the ulnar digital nerve of the small finger was found running deep to the distal third of the fat pad after branching from the ulnar nerve in Guyon's canal.

We concluded from these dissections that the pedicle from a flap of adipose tissue mobilized from the hypothenar area has a rich vascular supply provided by a series of segmental transverse arteries that emanate from the medial side of the ulnar artery. The deep dissection necessary to mobilize the flap is safe, provided it terminates as soon as the neurovascular structures in the canal of Guyon are visualized. In addition, the ulnar digital nerves to the small finger must be protected when mobilizing the distal aspect of the fat pad flap.

SURGICAL TECHNIQUE: THE HYPOTHENAR FAT PAD FLAP

The procedure is carried out under regional or general anesthesia. Through a linear incision be-



Figure 1. Latex arterial injection confirming multiple transverse branches arising from the ulna artery in Guyon's canal to provide a rich plexus to the hypothenar fat pad flap (HTFPF).

tween the thenar and hypothenar creases, a fat flap is raised by sharp subcutaneous dissection from the distal wrist crease to mid-palm (Fig. 2 and 3 A,B). Care is taken not to injure the digital nerves to the ring and small fingers while the undermining continues ulnarward for 2 cm. Deep mobilization of the flap is accomplished by excising a segment of the ulnar leaf of the transverse carpal ligament and elevating the flap by blunt and sharp dissection until the ulnar nerve and vessel are visualized in the canal of Guyon (Fig. 4 A,B). The flap then is tested to determine whether it can be advanced easily over the median nerve to the radial wall of the carpal canal (Fig. 5). If it has not been mobilized sufficiently, additional undermining is carried out, with care taken to preserve the ulnar pedicle of the flap and to not damage the ulnar nerve or artery. When ready, the fat pad flap is placed palmar to the median nerve and dorsal to the radial leaf of the transverse carpal ligament.

The contents of the canal are retracted ulnarward, with three horizontal mattress nonabsorbable sutures passed through the edge of the fat pad. These sutures are passed through the radial wall of the carpal tunnel adjacent to the flexor pollicis longus tendon and, finally, back through the fat pad. Sutures are tagged temporarily with a

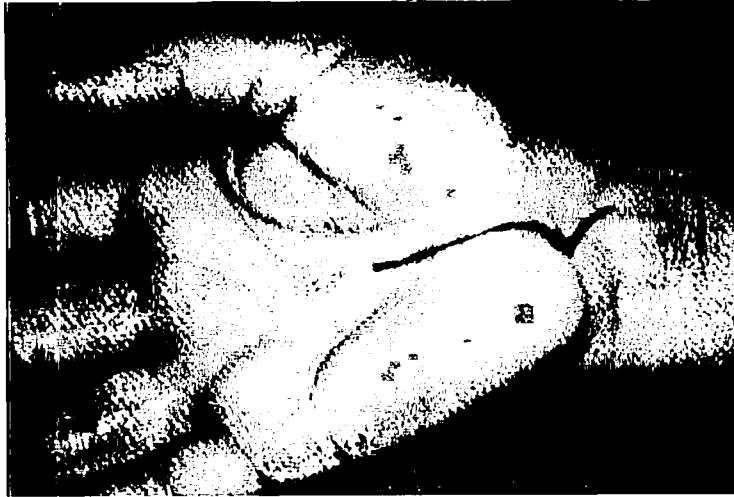


Figure 2. Skin incision for the hypothenar fat pad flap.

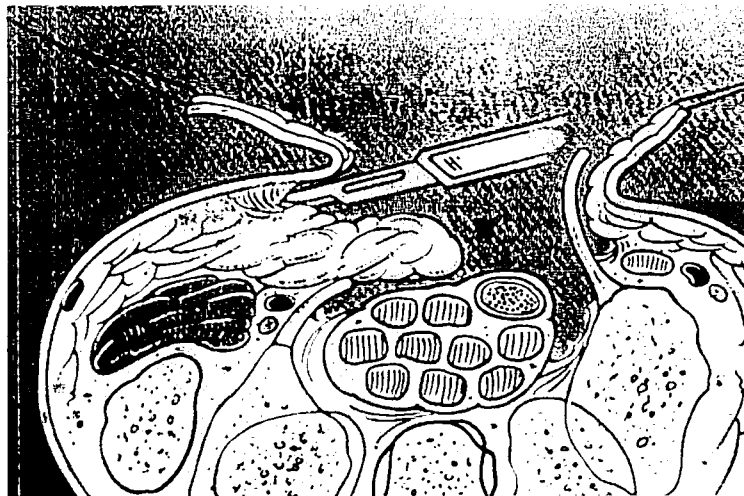
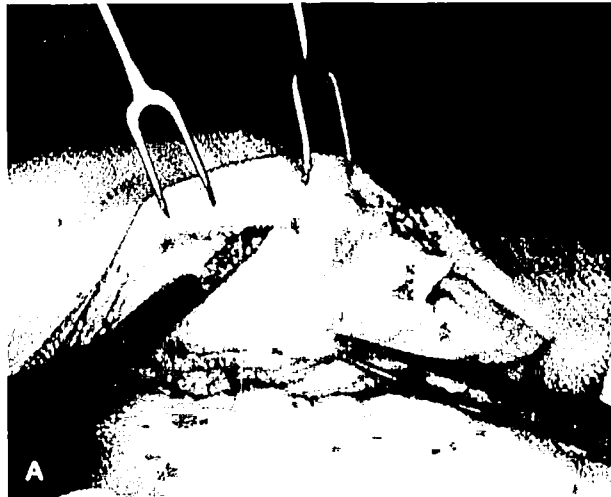

Figure 3. A, The hypothenar fat is raised by subcutaneous dissection in an ulnar direction. The median nerve is pictured at the bottom of the incision. Guyon's canal contents are just deep to the developed fat pad. B, An axial illustration. (Courtesy of Gary Schnitz, Indiana Hand Center.)

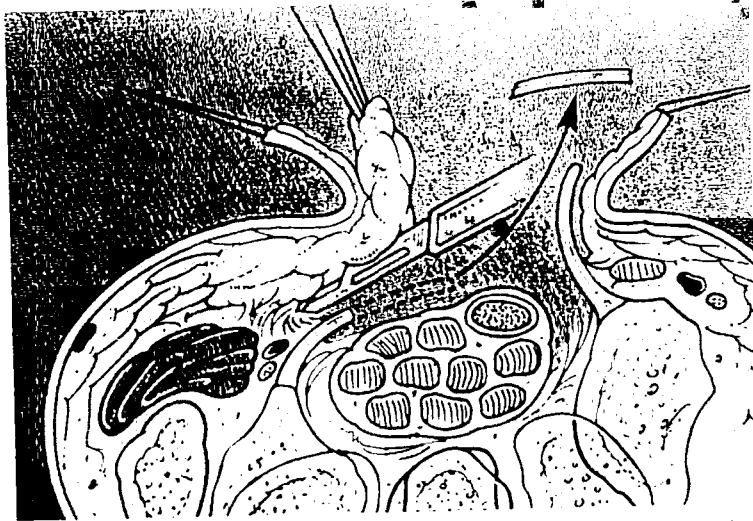
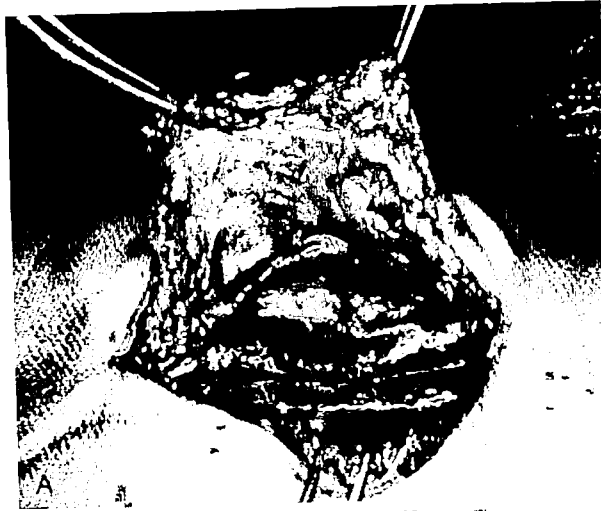

Figure 4. A, Deep mobilization of the fat pad with a segment of the ulnar leaf of the transverse carpal ligament excised. B, A corresponding axial illustration. (Courtesy of Gary Schnitz, Indiana Hand Center.)

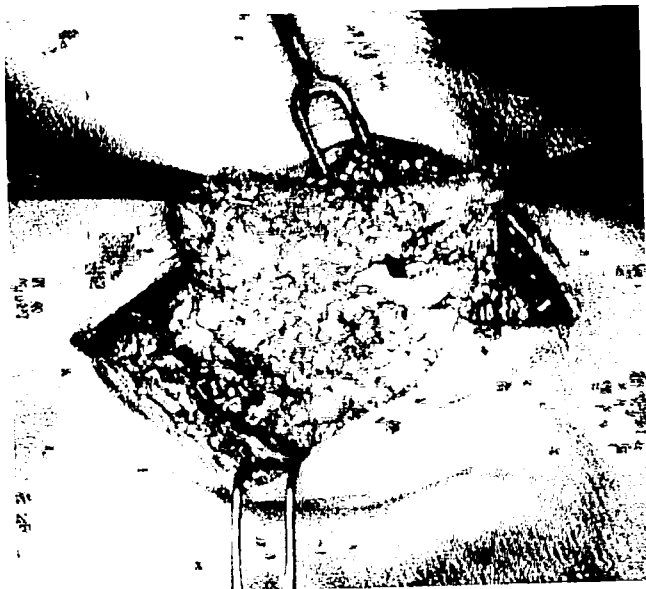

Figure 5. The HTFPF is tested to see if it advances easily over the

hemostat to facilitate the placement of all stitches prior to tying them in sequence (Fig. 6 A,B). When the sutures are tied, the radial and ulnar borders of the hand are compressed gently to ease the delivery of the flap down onto the radial side of the tunnel (Fig. 7 A,B).

Postoperatively, the hand is immobilized with gentle radial ulnar compression for 2 weeks with the wrist in neutral or slight dorsiflexion and the thumb abducted to relieve tension on the repair. Digital motion is encouraged during the course (4 weeks) of immobilization of the wrist. A protected range of motion with intermittent wrist splinting is continued for an additional 2 weeks, at which time full, unrestricted motion is permitted. Heavy lifting is not allowed until 6 weeks and supplemental therapy for strengthening and desensitization programs are instituted as necessary.

MR Imaging Scans

We performed T-1-weighted MR imaging studies on three patients early in the clinical use of this flap. The scan confirmed the position of the fat pad above the median nerve and below the radial leaf of the transverse carpal ligament at 3 days and greater than 2 years (Figs. 8-10). These findings helped verify that the fat pad remains vascularized after it is transferred.

Clinical Experience

We have used the hypothenar fat pad flap in over 80 patients since December, 1987. Each of our patients had two or more of the following criteria to be a candidate for this surgery:

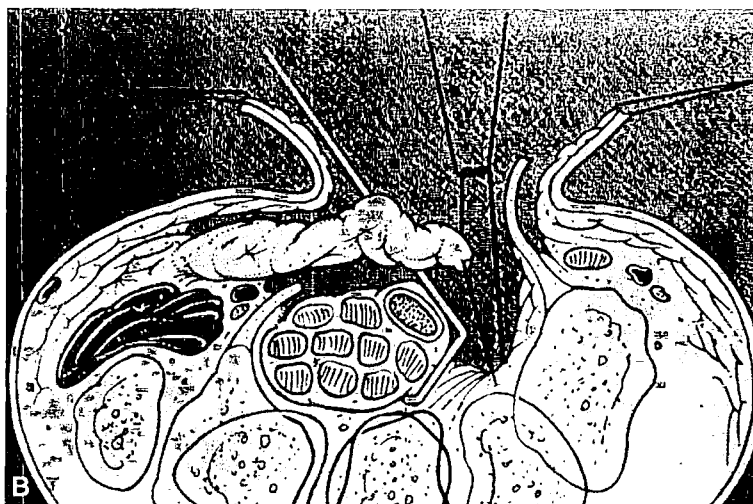
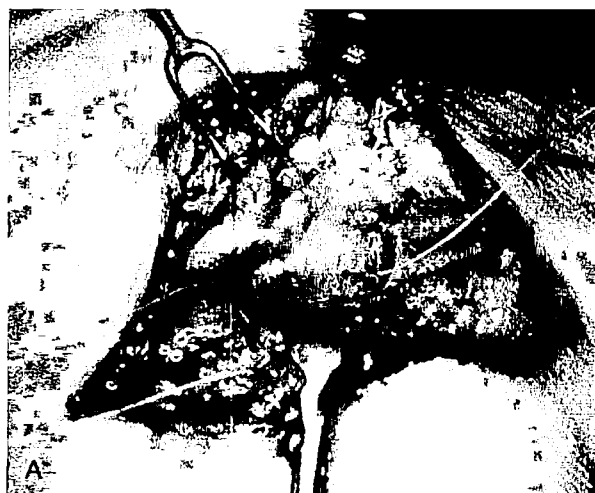

Figure 6. A, The carpal canal contents are retracted ulnar; mattress sutures are placed through the radial wall of the tunnel and back through the fat pad. B, A corresponding axial illustration. (Courtesy of Gary Schnitz, Indiana Hand Center.)

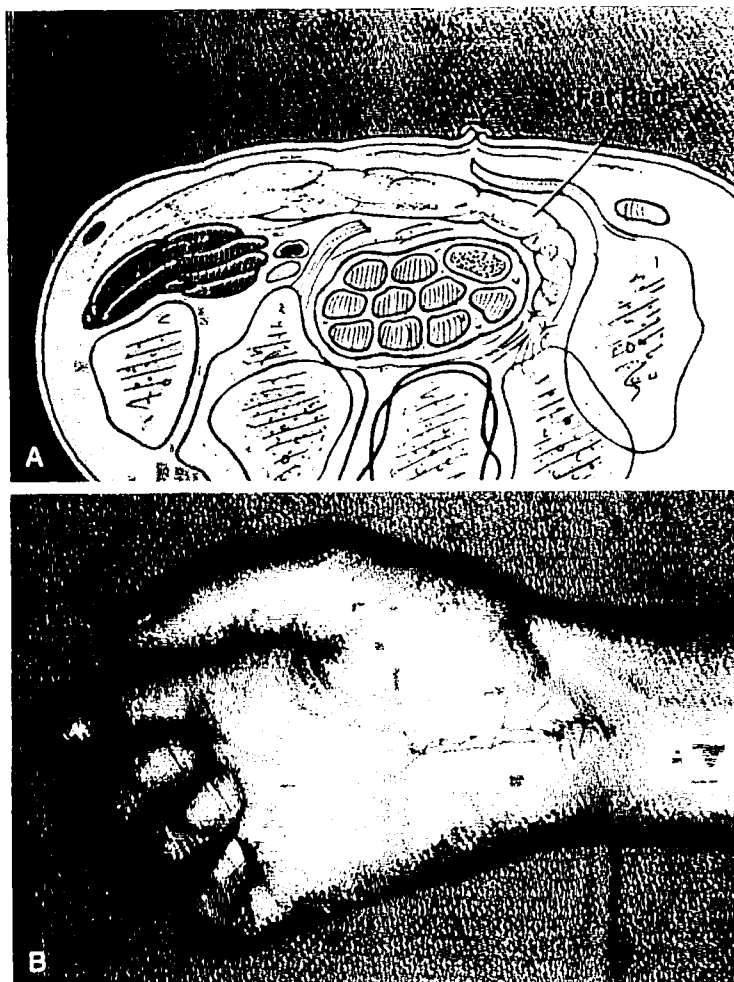


Figure 7. A, The fat pad placed palmar to the median nerve and dorsal to the radial leaf of the transverse carpal ligament. (Courtesy of Gary Schnitz, Indiana Hand Center.) B, Routine skin closure after hypothenar fat pad closure.

1. Persistent or recurrent median nerve symptoms at the wrist or fingers after adequate open surgical decompression.
2. Significant palmar hypersensitivity or proximal pain migration without permanent damage to the palmar cutaneous branch of the median nerve.
3. A progressive neurologic deficit, including thenar muscle atrophy or expanded two-point sensory discrimination as determined by the Weber two-point discrimination test using a dull pointed eye caliper applied in the longitudinal axis of the digit without blanching the skin.²⁹
4. Failure of conservative treatment, including splinting, injection, and the passage of time.
5. No concomitant major wrist surgery, either soft tissue or bony in nature.

We reviewed our initial 62 patients several years

ago. There were 16 Worker's Compensation and 46 non-Worker's Compensation patients. The age distribution is shown in Figure 11. There was a minimum follow-up of 1.5 years. Patient satisfaction is shown for both groups in Figure 12.

Subjective complaints were evaluated. Pain that began in the hands and migrated toward the elbow and shoulder was completely alleviated in all groups with the hypothenar fat pad flap (Fig. 13). Nocturnal pain also was improved (Fig. 14). Ninety percent of patients had relief of their dysesthesias and paraesthesias. Not all patients who had an expanded two-point discrimination preoperatively returned to normal two-point discrimination (< 6 mm).

Objective data revealed that not all Tinel's and Phalen's signs, when present preoperatively, were resolved, yet patient satisfaction rates remained very high (Figs. 15, 16). Grip strength increased

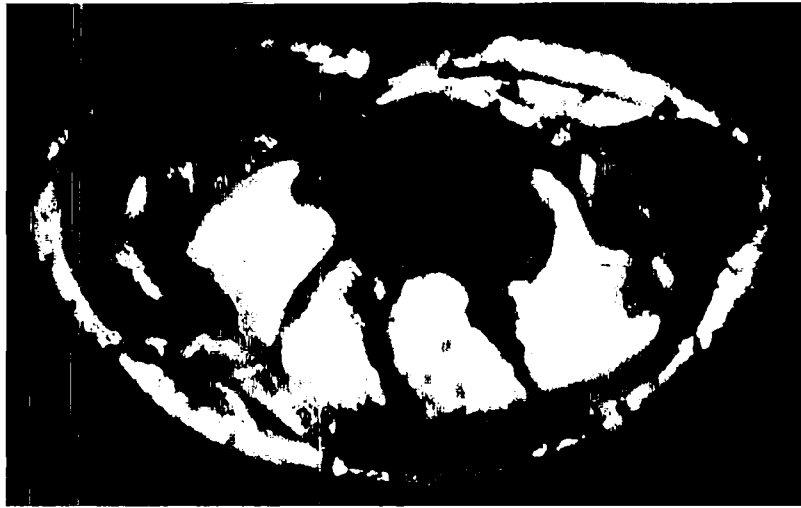

Figure 8. T-1 weighted MR imaging studies performed preoperatively, showing the superficial position of the median nerve, along with the transverse carpal ligament, and the rich reservoir of hypothenar fat.

Figure 9. The same patient postoperatively, showing the median nerve well within the carpal canal and protected by the hypothenar fat pad flap.

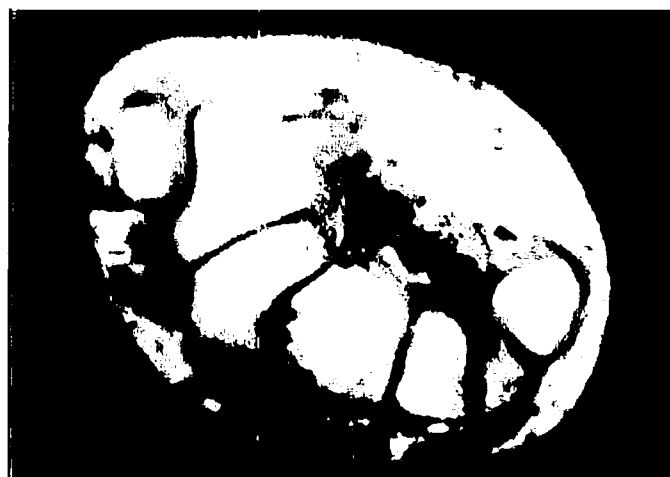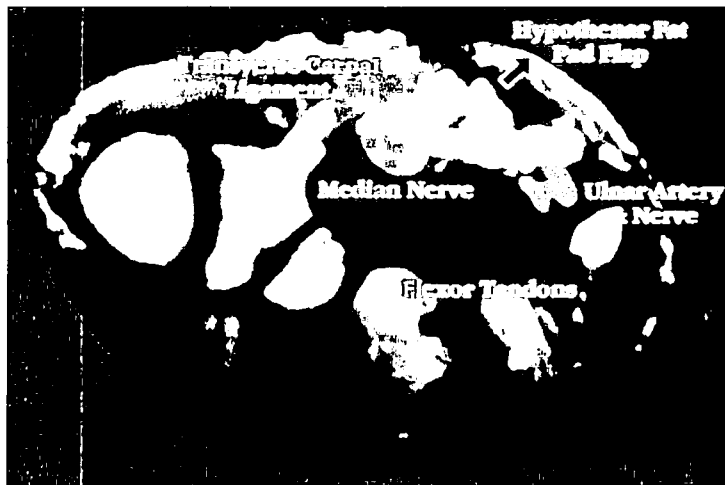


Figure 10. A long-term scan approximately 2 years postoperatively, showing the persistence of the hypothenar fat pad flap.

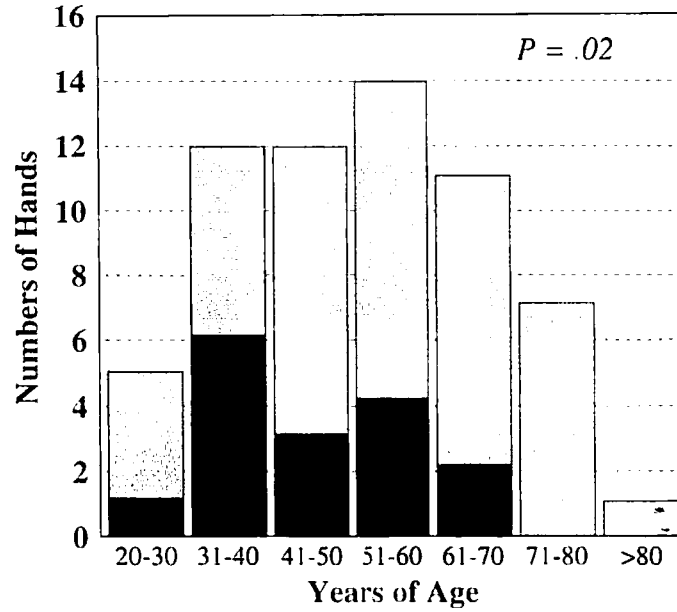


Figure 11. Bar graph of the age distribution for the workers' compensation (n = 16) (WKC) and the nonworkers' compensation (n = 46) (NWKC) groups. Black bar = WKC; shaded bar = NWKC.

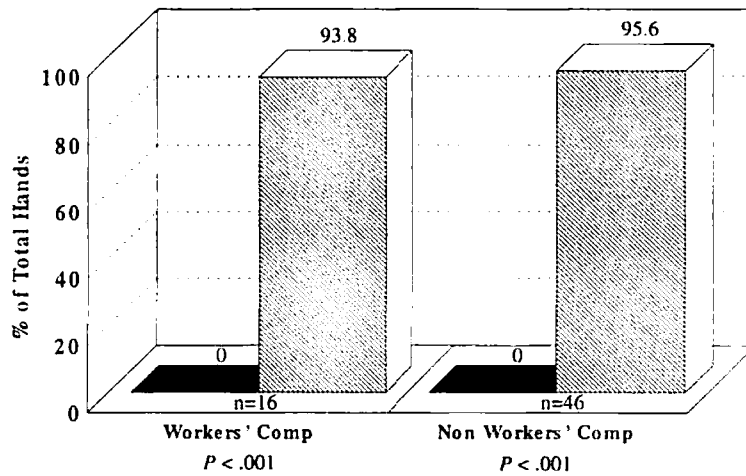


Figure 12. Bar graph of patient satisfaction with the HTFPF at 33 months follow-up. Black area = pre-op; diag bar = post-op.

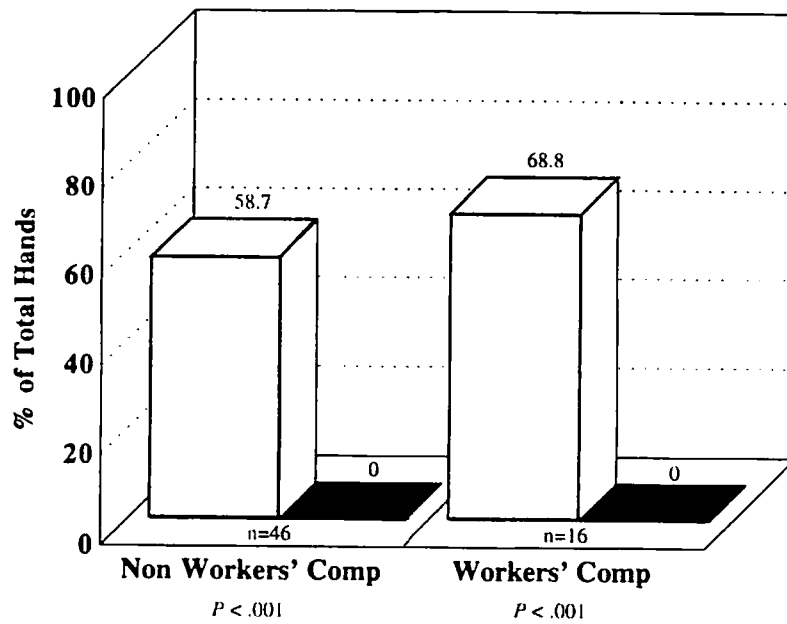


Figure 13. Graph showing the percentage of hands with the pre- and postoperative finding of proximal pain migration in the WKC and non-WKC groups. Shaded bar = pre-op; black area = post-op.

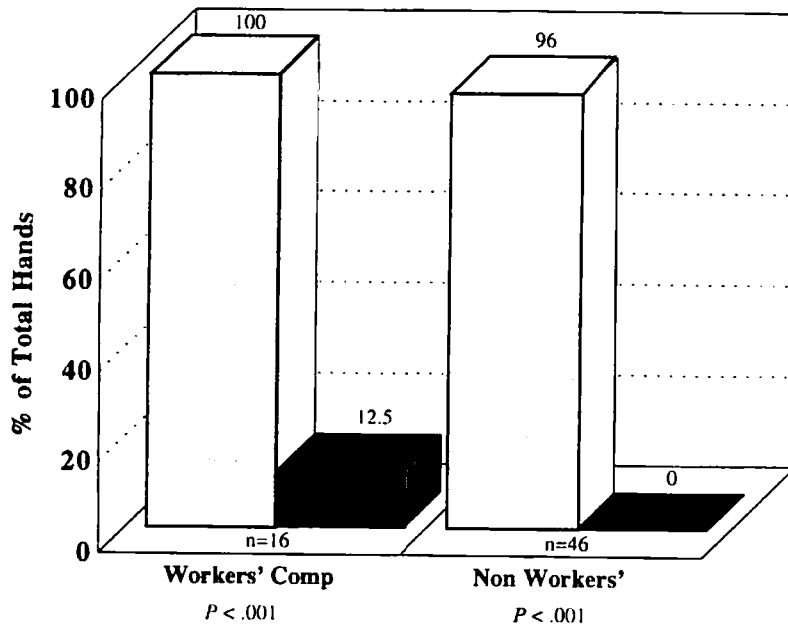


Figure 14. Graph of palmar pain (night pain for patients post failed carpal tunnel release and post HTFPF). Shaded bar = pre-op; black = post-op.

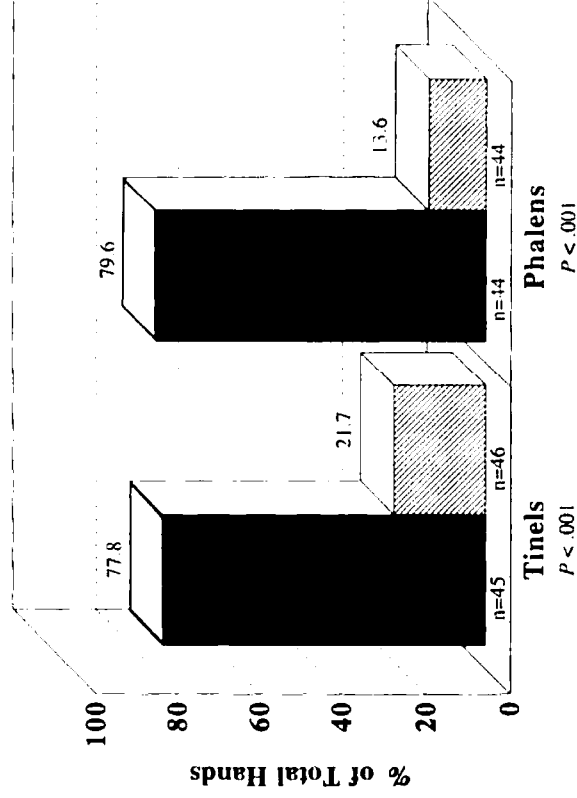


Figure 15. Graph illustrating Tinel's and Phalen's sign in the Workers' Compensation Group. Black bar = pre-op; diagonal bar = post-op.

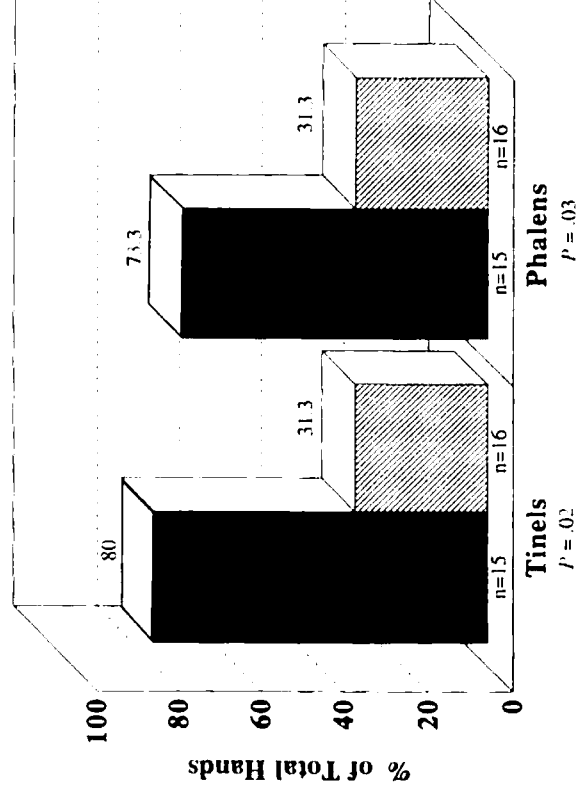


Figure 16. Graph illustrating Tinel's and Phalen's sign in the non Workers' Compensation Group. Black bar = pre-op; diagonal bar = post-op.

85% and overall pinch, when measured, improved 8.5%.

ALTERNATIVES TO THE HYPOTHENAR FAT PAD FLAP

Open carpal tunnel release is one of the procedures most frequently performed in the hand. It often is the procedure of choice for those who have not responded to conservative management for compression of the median nerve at the wrist.^{22, 23} Satisfactory relief of paresthesias, dysesthesias, and hypesthesias, as well as patient satisfaction because of lasting alleviation of symptoms often result. In fact, alleviation of symptoms from idiopathic carpal tunnel syndrome has been achieved in more than 80% of patients.^{4, 9, 10, 15, 20, 23}

It is disappointing for both patient and surgeon, however, that approximately 20% of patients are not relieved by a carpal tunnel release.^{1, 4, 9, 10, 15, 20} These few patients with recurring symptoms often require a lot of attention. At surgery, the finding of perineural and intraneural scarring with adherence of the median nerve to the radial leaf of the transverse carpal ligament is predictable. Nonoperative treatment and re-exploration with neurolysis frequently fail to provide long-term benefits because the median nerve again becomes trapped in scar that adheres to the transverse carpal ligament.^{2, 10, 26, 32} The hypothenar fat pad flap is an alternative operative procedure designed to decrease the morbidity associated with a failed decompression of the median nerve.

Several surgical procedures (Table 1) have been described and used to relieve the symptoms of recalcitrant carpal tunnel syndrome. These techniques try to provide a healthy, vascularized pedicle of tissue with size sufficient to allow complete coverage of the median nerve and to prevent readherence to the transverse carpal ligament.

The palmaris brevis flap, as described recently by Rose,²⁵ although stated to be absent in only 2% of patients, has proved to be absent or of insufficient size in a much higher percentage of hands.¹² Dellon⁵ has detailed the use of the pronator quadratus muscle flap to bring a vascularized muscle distal for coverage of the median nerve. This flap, based on its proximal pedicle, is difficult to mobilize and transfer on a vascular pedicle of length

sufficient to provide coverage of the entire median nerve in the proximal palm. Wulle³² described the use of an ulnar pedicle synovial flap in conjunction with neurolysis of the median nerve. This flap, like the recommendations of Wintsch,²² creates a gliding bed for the neurolyzed median nerve but may not provide adequate padding and, to date, its long-term status is unknown. The free flap of gliding tissue of Wintsch requires a large and technically demanding dissection from a tissue that is not available locally.³¹ Hagen⁷ has recommended a widening Z-plasty to reconstruct the flexor retinaculum to avoid palmar subluxation of the median nerve. Hagen and coauthors⁷ admit this finding is present only 60% of the time and therefore may not be practical in all patients with recalcitrant carpal tunnel. Wilgis³⁰ promoted the lumbrical flap as a reliable technique for coverage of the median nerve in the carpal tunnel. The lumbrical flap relies on a small muscle that must be mobilized on its pedicle and, in our experience, cannot always provide sufficient proximal coverage of the nerve.³⁰ Finally, Milward et al¹⁸ and, later, Reisman²⁴ and Ruby,¹³ as well as Buck-Gramcko,²⁷ all have used the abductor digiti minimi muscle flap for improved coverage of the neurolyzed median nerve. This flap does provide a thick, well-vascularized muscle for coverage but requires an extensive dissection and sacrifices an important hypothenar muscle. The technique requires a long arc of rotation and the patient postoperatively may have a partial limitation of small finger abduction.

In contrast to the aforementioned procedures, the hypothenar fat pad flap is locally available and expendable. Its mobilization is technically simple and safe and yields few, if any, postoperative complications. This flap provides a healthy tissue environment to prevent readherence of the median nerve to the transverse carpal ligament. The hypothenar eminence is a rich reservoir of well-vascularized adipose tissue that easily can be raised as a flap on its ulnar pedicle and, because of its sufficient size, can be advanced to cover the median nerve completely.

Although the hypothenar fat pad flap is not difficult technically, there are several points that should be emphasized:

1. Palmar undermining should be kept in the subcutaneous plane to avoid damage to the ulnar digital nerve to the small finger.

Table 1. SURGICAL PROCEDURES USED FOR MEDIAN NERVE COVERAGE IN RECALCITRANT CARPAL TUNNEL SYNDROME

Flap Procedure	Author
1. The abductor digiti minimi muscle flap	(Milward, 1977) ¹⁸
2. The lumbrical flap	(Wilgis, 1984) ³⁰
3. The pronator quadratus muscle flap	(Dellon, 1984) ⁵
4. Free flap of gliding tissue	(Wintsch, 1986) ³¹
5. The ulnar pedicle synovial flap	(Wulle, 1987) ³²
6. The palmaris brevis turnover flap	(Rose, 1991) ²⁵
7. The hypothenar fat pad flap	(Cramer 1985, Strickland 1996) ³

2. A portion of the ulnar leaf of the previously divided transverse carpal ligament usually is resected.
3. Deep mobilization terminates with the visualization of the ulnar nerve and artery in the canal of Guyon.
4. The flap should be raised until it easily will reach the dorsal radial wall of the carpal canal, where it is sutured in place adjacent to the flexor pollicis longus tendon.
5. The hand needs to be immobilized with a fair amount of radial ulnar compression for 2 weeks.

Complications

The safety of a new technique is always a major concern for a surgeon selecting a procedure. We had three transient complications in our early series of 62 patients. Paresthesias in the ulnar digital nerve of the small finger were seen in one patient, which may have been attributable to the surgeon becoming acquainted with the operative technique and being overzealous in the dissection by placing too much traction on the flap as it was mobilized. Numbness in the hypothenar eminence was seen in another patient, which may have resulted from inadvertent injury to the palmar cutaneous branch of the ulnar nerve.⁶ The last complication was a superficial cellulitis that responded to oral antibiotic administration in 6 weeks. The patient admitted he went back to farming with his dressing off only several days after surgery. There were no permanent complications.

SUMMARY

Open decompression of the median nerve generally is so effective that little is mentioned of the surgical treatment options for recalcitrant or unrelieved carpal tunnel syndrome. The hypothenar fat pad flap has been shown to be a reliable local source of well-vascularized adipose tissue that can be used for coverage of the median nerve during re-exploration of recurrent or persistent idiopathic carpal tunnel syndrome. The hypothenar fat pad flap is a technically simple procedure that allows the fat pad to be mobilized easily and placed across the palm as a barrier between the nerve and the radial leaf of the transverse carpal ligament, effectively preventing median nerve readherence. This flap hopefully will improve the tissue environment for the median nerve, permitting it to have normal excursion during wrist motion. Our results to date have been better than previously described for other techniques. We believe the hypothenar fat pad flap should be considered in the hand surgeon's armamentarium for recalcitrant idiopathic carpal tunnel syndrome.

References

1. Bloem JJ, Pradjarahardja MCL, Vuursteen PJ: The post-carpal tunnel syndrome: Causes and prevention. *Netherlands Journal of Surgery* 38:52-55, 1986
2. Conolly WB: Pitfalls and carpal tunnel decompression. *Aust N Z J Surg* 48:421-425, 1978
3. Cramer LM: Local fat coverage for the median nerve. *In* Lankford LL (ed): *Correspondence Newsletter for Hand Surgery*. 1985, p 35
4. Cseuz KA, Thomas JE, Lambert EH, et al: Long-term results of operation for carpal tunnel syndrome. *Mayo Clin Proc* 41:232-241, 1966
5. Dellon AL, Mackinnon SE: The pronator quadratus muscle flap. *J Hand Surg* 9A:423-427, 1984
6. Engber WD, Gmeiner JG: Palmar cutaneous branch of the ulnar nerve. *J Hand Surg* 5A:26-29, 1980
7. Hagen VK, Sennwald G: Das Karpaltunnelsyndromrezidiv. problematik und behandlung. *Handchir Mikrochir Plast Chir* 22:309-311, 1990
8. Hunter JM: Recurrent carpal tunnel syndrome, epineural fibrous fixation, and traction neuropathy. *Hand Clinics* 7:491-504, 1991
9. Kulich MI, Gordillo G, Javidi T, et al: Long-term analysis of patients having surgical treatment for carpal tunnel syndrome. *J Hand Surg* 11A:59-66, 1986
10. Langlosh ND, Linscheid RL: Recurrent and unrelieved carpal-tunnel syndrome. *Clin Orthop* 83:41-47, 1972
11. Learmonth GR: The principles of decompression in the treatment of certain diseases of peripheral nerves. *Surg Clin North Am* 13:905-913, 1933
12. LeDouble AF: *Traite des variations du systeme musculaire de l'homme et leur signification au point de vue de l'arthropologie zoologique*. Paris, Schleicher Freres, 1897, pp 170-171
13. Leslie BM, Ruby LK: Coverage of a carpal tunnel wound dehiscence with the abductor digiti minimi muscle flap. *J Hand Surg* 13A:36-39, 1988
14. Louis DS, Greene TL, Noellert RC: Complications of carpal tunnel surgery. *J Neurosurg* 62:352-356, 1985
15. MacDonald RI, Lichtman DM, Hanlon JJ, et al: Complications of surgical release for carpal tunnel syndrome. *J Hand Surg* 3A:70-76, 1978
16. Mackinnon SE: Secondary carpal tunnel surgery. *Neurosurg Clin N Am* 2:75-91, 1991
17. Marie F, Foix C: Atrophie isolée de l'eminence thénar d'origin nevritique. role du ligament annulaire antérieur du carpe dans la pathogénie de la lésion. *Rev Neurol* 26:647-649, 1913
18. Milward TM, Stott WG, Kleinert HE: The abductor digiti minimi muscle flap. *Hand* 9:82-85, 1977
19. Paget J: *Lectures on Surgical Pathology*. Philadelphia, Lindsay and Blakestone, 1854, p 42
20. Phalen GS: Spontaneous compression of the median nerve at the wrist. *JAMA* 145:1128-1132, 1951
21. Phalen GS: The carpal tunnel syndrome: 17 years' experience in diagnosis and treatment of 654 hands. *J Bone Joint Surg* 48-A:211-228, 1966
22. Phalen GS: Reflections on 21 years' experience with the carpal-tunnel syndrome. *JAMA* 212:1365-1367, 1970
23. Phalen GS: The carpal-tunnel syndrome: Clinical evaluation of 598 hands. *Clin Orthop* 83:29-40, 1972
24. Reisman NR, Dellon AL: The abductor digiti minimi muscle flap: A salvage technique for palmar wrist pain. *Plast Reconstr Surg* 72:859-863, 1983
25. Rose EH, Norris MS, Kowalski TA, et al: Palmaris brevis turnover flap as an adjunct to internal neurolysis of the chronically scarred median nerve in recurrent carpal tunnel syndrome. *J Hand Surg* 16A:191-201, 1991

26. Smet LD: Recurrent carpal tunnel syndrome: Clinical testing indicating incomplete section of the flexor retinaculum. *J Hand Surg* 18B:189, 1993
27. Ulmer J, Buck-Gramcko D: Der neurovaskular gestielte abductor digiti minimi-muskellappen zur abdeckung des n. medianus oder seiner aste. *Handchirurgie* 20:338-341, 1988
28. Urbaniak JR: Complications of treatment of carpal tunnel syndrome. In Gelberman R (ed): *Operative Nerve Repair and Reconstruction*. Philadelphia, JB Lippincott, 1991, vol 2, pp 967-979
29. Werner JL, Omer GE: A procedure evaluating cutaneous pressure sensation of the hand. *Am J Occup Ther* 24:347-356, 1970
30. Wilgis EFS: Local muscle flaps in the hand anatomy as related to reconstructive surgery. *Bull Hosp Jt Dis* 44:552-557, 1984
31. Wintch K, Helaly P: Free flap of gliding tissue. *J Reconstr Microsurg* 2:143-151, 1986
32. Wulle C: Treatment of reoccurrence of the carpal tunnel syndrome. *Ann Chir Main Memb Super* 6:203-209, 1987

Address reprint requests to
Kevin D. Plancher, MD, MS
Montefiore Medical Center
Department of Orthopaedics
111 E. 210th Street
Bronx, NY 10467