

# Symptomatic Scapulothoracic Crepitus and Bursitis

John E. Kuhn, MD, Kevin D. Plancher, MD, and Richard J. Hawkins, MD

## Abstract

Scapulothoracic crepitus and scapulothoracic bursitis are related painful disorders of the scapulothoracic articulation. Scapulothoracic crepitus is the production of a grinding or snapping noise with scapulothoracic motion, which may be accompanied by pain. Scapulothoracic bursitis manifests as pain and swelling of the bursae of the scapulothoracic articulation. Scapulothoracic bursitis is always seen in patients with symptomatic scapulothoracic crepitus, but may exist as an isolated entity. Symptomatic scapulothoracic crepitus may be due to pathologic changes in the bone or soft tissue between the scapula and the chest wall or may be due to changes in congruence of the scapulothoracic articulation, as seen in scoliosis and thoracic kyphosis. Treatment of patients with symptomatic scapulothoracic crepitus begins with nonoperative methods, including postural and scapular strengthening exercises and the application of local modalities. When soft-tissue lesions are the cause of scapulothoracic crepitus, conservative treatment is highly effective. When symptomatic scapulothoracic crepitus is due to osseous lesions, or when conservative treatment has failed, surgical options are available. Partial scapulectomies have produced satisfactory outcomes in selected patients. Recently, open and arthroscopic scapulothoracic bursectomies have been performed with some success and are being used more frequently.

J Am Acad Orthop Surg 1998;6:267-273

Painful scapulothoracic crepitus and scapulothoracic bursitis, although relatively infrequent, are among the more common disorders of the scapulothoracic articulation. These disorders can be annoying, painful, and even disabling to the patient. It is important to understand that there are subtle differences between these two related disorders. Milch<sup>1</sup> identified two types of scapulothoracic crepitus. An osseous lesion, such as an osteochondroma in the scapulothoracic space, will produce a loud grating or thumping sound, which is frequently associated with pain. Milch termed this type of severe scapulothoracic crepitus the "snapping scapula." The other, less in-

tense symptomatic scapulothoracic crepitus is thought to originate from some soft-tissue disorder, such as bursitis. It is important to appreciate that painful scapulothoracic bursitis may be present without associated crepitus, and that asymptomatic scapulothoracic crepitus may be physiologic. An understanding of these two related but different disorders will assist the physician in diagnosing and treating these conditions.

## Scapulothoracic Bursitis

### Pathoanatomy

The distinctive anatomy of the subscapular region is not well ap-

preciated, and the scapulothoracic bursae are frequently neglected or incompletely discussed in standard anatomy texts. Nevertheless, two major (anatomic) bursae and four minor (adventitious) bursae have been described for the scapulothoracic articulation (Table 1, Fig. 1).

The first major bursa is found in the space between the serratus anterior muscle and the chest wall. The second major bursa is located between the subscapularis and serratus anterior muscles.<sup>2,3</sup> These bursae are easily and reproducibly found, both in anatomic specimens and on arthroscopic examination.<sup>3</sup>

Clinical scapulothoracic bursitis seems to affect two areas of the scapulothoracic articulation, the superomedial angle and, less commonly, the inferior angle. In the symptomatic patient, inflamed bur-

Dr. Kuhn is Assistant Professor, Division of Sports Medicine, Section of Orthopaedic Surgery, University of Michigan Medical Center, Ann Arbor. Dr. Plancher is Assistant Professor, Albert Einstein College of Medicine, New York; and Hand Consultant, Steadman-Hawkins Clinic, Vail, Colo. Dr. Hawkins is Clinical Professor, Department of Orthopedics, University of Colorado Medical School, Denver; and Orthopaedic Consultant, Steadman-Hawkins Clinic, Vail.

Reprint requests: Dr. Kuhn, University of Michigan Shoulder Group, 24 Frank Lloyd Wright Drive, Box 0363, Ann Arbor, MI 48106.

Copyright 1998 by the American Academy of Orthopaedic Surgeons.

**Table 1**  
**Types and Locations of Bursae of the Scapulothoracic Articulation**

Type	Location
<b>Major (anatomic) bursae</b>	
Infraserratus bursa	Between serratus anterior muscle and chest wall
Supraserratus bursa	Between subscapularis and serratus anterior muscles
<b>Minor (adventitial) bursae</b>	
Superomedial angle of the scapula	
Infraserratus bursa	Between serratus anterior muscle and chest wall
Supraserratus bursa	Between supscapularis and serratus anterior muscles
Inferior angle of the scapula	
Infraserratus bursa	Between serratus anterior muscle and chest wall
Spine of scapula	
Trapezoid bursa	Between medial spine of scapula and trapezius muscle

sae in these areas are minor bursae and may not be present in the absence of inflammation. Some authors believe that these bursae are adventitial and develop in response to abnormal pathomechanics of the scapulothoracic articulation.<sup>3-5</sup> It is not surprising, therefore, to find that these bursae occur inconsistently and in different soft-tissue planes.

Most authors agree that the bursa that occurs at the inferior angle of the scapula lies between the serratus anterior muscle and the chest wall.<sup>1,6,7</sup> This bursa has been given several names, among them the infraserratus bursa<sup>6</sup> and the bursa mucosa serrata.<sup>1</sup>

A second site of pathologic change is at the superomedial angle of the scapula. Codman<sup>6</sup> believed this bursa is also an infraserratus bursa, lying between the upper anterior portion of the scapula and the back of the first three ribs. However, von Gruber, writing in 1864, identified a bursa in this region between the subscapularis

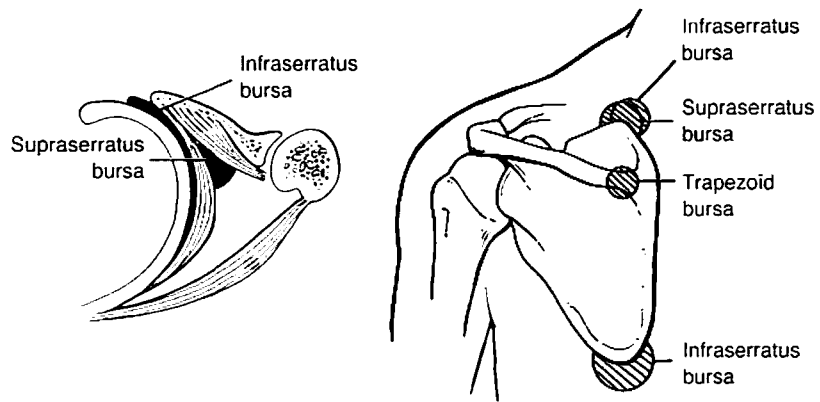
and serratus anticus muscles, which he called the bursa mucosa angulae superioris scapulae.

A third minor bursa, which Codman<sup>6</sup> believed was the site of

painful crepitus in scapulothoracic crepitus, is called the trapezoid bursa. This is found over the triangular surface at the medial base of the spine of the scapula under the trapezius muscle.

### Diagnosis

Scapulothoracic bursitis may accompany painful scapular crepitus or may exist as a separate entity. Patients generally complain of pain with activity and may have audible and palpable crepitus of the scapulothoracic articulation. The scapular crepitus associated with bursitis is usually much less intense than that which occurs with a bone lesion. Patients relate a history of trauma<sup>8,9</sup> or overuse due to sports activities or work,<sup>7,9,10</sup> which produces repetitive or constant movement of the scapula on the posterior thorax. This type of activity may irritate soft tissues until chronic bursitis and inflammation develop. The bursa then undergoes scarring and fibrosis, with crepitus and pain occurring as secondary phenomena.



**Fig. 1** Anatomic and adventitial bursae of the scapulothoracic articulation. Left, The infraserratus bursa is found between the serratus and the chest wall. Its borders are the origin of the serratus laterally and the rhomboid muscles medially. The supraserratus bursa is found between the serratus anterior and the subscapularis, with the lateral border extending to the axilla and the medial border extending to the insertion of the serratus. Right, Sites where symptomatic bursitis may occur and the bursae that are affected. (Reproduced with permission from Kuhn JE, Hawkins RJ: Evaluation and treatment of scapular disorders, in Warner JJP, Iannotti JP, Gerber C (eds): *Complex and Revision Problems in Shoulder Surgery*. Philadelphia: Lippincott-Raven, 1997, pp 357-375.)

Physical findings in patients with scapulothoracic bursitis include tenderness to palpation and a doughy fullness over the bursa. A mild or moderate amount of scapular winging may be present.

The differential diagnosis of scapulothoracic bursitis includes elastofibroma, which is a benign tumor characterized by a matrix of eosinophils interspersed with elastin fibers. This tumor is most commonly seen in the infrascapular region in patients over 55 years of age.

### Treatment

Regardless of which bursa is affected, the initial treatment of scapulothoracic bursitis is nonoperative, beginning with rest, analgesics, and nonsteroidal anti-inflammatory drugs. Physical therapy and local corticosteroid injections have also been recommended.<sup>7,10</sup> Corticosteroid injections, administered no more than three or four times a year, may have both diagnostic and therapeutic value. Patients who respond well to corticosteroid injections will be more likely to have a successful outcome from surgery if that becomes necessary. Care must be taken with injections near the scapulothoracic articulation, however, as pneumothorax is a potential complication.<sup>11</sup> The application of local modalities, such as ice, heat, and ultrasound, may help reduce pain.

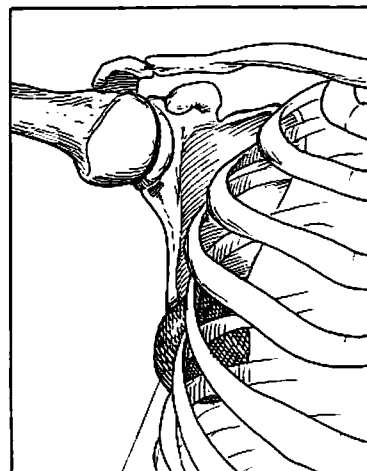
Periscapular muscle-strengthening exercises are frequently helpful.<sup>7,10</sup> The rehabilitation program should focus on maintenance of upright posture to reduce thoracic kyphosis and development of the serratus anterior and subscapularis muscles to enhance the soft tissue between the scapula and the chest wall. Exercises, including the "push-up plus" (a push-up with increased protraction of the scapula) and internal rotation strengthening, carried out daily over a 3-month period may help reduce the severity of

symptoms. For patients who continue to have symptoms despite appropriate nonoperative treatment, surgery may be considered.

Sisto and Jobe<sup>7</sup> described an open procedure for resecting a bursa at the inferior angle of the scapula in four major-league baseball pitchers. All pitchers had pain during early cocking, late cocking, and acceleration and could no longer pitch (Fig. 2). Only one of the four demonstrated scapulothoracic crepitus, but all had a palpable bursal sac ranging in size from 1 to 2 cm in diameter, best seen with the arm abducted to 60 degrees and elevated forward 30 degrees. Nonoperative therapy was unsuccessful in all cases. Bursal excision was performed through an oblique incision just distal to the inferior angle of the scapula. The trapezius muscle and then the latissimus dorsi muscle were split in line with their fibers, exposing the bursa. The bursa was sharply excised, and any osteophytes on the inferior pole of

the scapula or ribs were removed. The wounds were closed routinely over a drain, and a compression dressing was applied. Physical therapy stressing motion was begun after 1 week and then progressed to allow gentle throwing at 6 weeks. Activity was increased as symptoms abated, permitting a return to the former level of pitching by all four patients.

Similarly, McCluskey and Bigliani<sup>9,10</sup> performed open excision of a symptomatic superomedial scapulothoracic bursa in nine patients. They noted an abnormal thickened bursa between the serratus anterior and the chest wall at the time of surgery. With their surgical technique, a vertical incision is made medial to the vertebral border of the scapula. The trapezius is dissected free, and a subperiosteal dissection is used to free the levator scapulae and rhomboids from the medial border of the scapula. A plane is developed between the serratus anterior and the chest wall. The thickened bursa



Infraserratus bursa

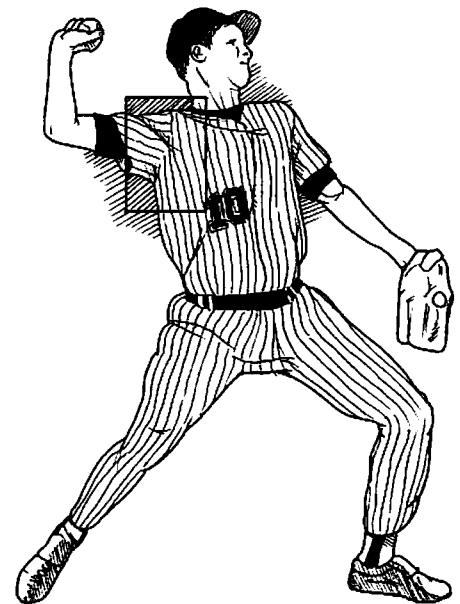

Fig. 2 Frequent location of inferior-angle scapulothoracic bursitis in baseball pitchers. A bursa is thought to develop under the inferior angle of the scapula in the infraserratus region, as a result of high forces generated during the cocking phase of throwing.

is resected, and any osseous projections are removed. The medial periscapular muscles and trapezius are reapproximated to the scapula. The skin is closed in a routine fashion. The patient uses a sling for comfort and begins passive motion and pendulum exercises immediately. Active motion is allowed at 3 weeks, and strengthening is begun at 12 weeks. With this technique, 8 (89%) of 9 patients with symptomatic scapulothoracic bursitis had good or excellent results. One patient with a fair result also required muscle transfers for trapezius winging.

Resection of the symptomatic scapulothoracic bursa has been performed arthroscopically as well.<sup>2,3,12</sup> Ciullo and Jones<sup>2</sup> have reported the largest arthroscopic series to date, with 13 patients who underwent subscapular endoscopy for symptomatic scapulothoracic bursitis after a nonoperative treatment program proved unsuccessful. Fibrous adhesions in the bursa between the subscapularis and serratus muscles and in the bursa between the serratus and the chest wall were debrided. Scapulothoracic or debridement of abnormal tissue at the superomedial angle or inferior angle was also performed. All 13 patients returned to their preinjury activity level except for physician-imposed restrictions in a few cases, in which the assembly-line use of vibrating tools was limited.

The early results with the use of arthroscopic techniques for performing a scapulothoracic bursectomy seem promising, with no reported cases of injury to the long thoracic nerve, dorsal scapular artery, suprascapular nerve, axillary contents, or contents of the thoracic cavity. Despite this, no large series of cases of arthroscopic treatment of scapulothoracic bursitis has yet been reported in the peer-reviewed literature, and it must be emphasized that this technique remains investigational at this time,

with the pitfalls not clearly defined due to limited clinical experience.

## Scapulothoracic Crepitus

### Pathoanatomy

It is important to realize that scapulothoracic crepitus is not necessarily a pathologic condition. Grünfeld<sup>13</sup> reported finding scapular crepitus in 31% of 100 normal asymptomatic persons. Codman stated that he was able to make his own scapula "sound about the room without the slightest pain."<sup>6</sup> It must be borne in mind, therefore, that patients with the potential for secondary gain or psychiatric conditions may not respond to treatment as well as other patients do. However, if the scapulothoracic crepitus is truly associated with pain, winging, or other disorders of the scapulothoracic articulation, it is considered to be pathologic.

Symptomatic scapulothoracic crepitus has been given a variety of names, including snapping scapula,<sup>1</sup> washboard syndrome,<sup>2</sup> scapulothoracic syndrome,<sup>14</sup> rolling scapula,<sup>1</sup> grating scapula,<sup>15</sup> and scapulothoracic syndrome.<sup>16</sup> Boinet, in 1867, was the first to describe this disorder. Thirty-seven years later, Mauclair classified scapulothoracic crepitus into three types: froissement (a gentle friction sound thought to be physiologic), frottement (a louder sound with grating, which is usually pathologic), and craquement (a loud snapping sound, which is always pathologic). Extrapolating from Milch,<sup>1</sup> frottement may suggest a soft-tissue lesion or bursitis, while craquement may suggest an osseous lesion as the source of symptomatic scapulothoracic crepitus.

These scapular noises are thought to arise from two sources: (1) anatomic changes in the tissue interposed between the scapula and the chest wall and (2) an incongruent scapulothoracic articulation<sup>1</sup> (Table 2). The noises are amplified by the air-filled

thoracic cavity, which acts as a resonating chamber, much like a stringed instrument.<sup>17</sup> Scapulothoracic crepitus may be due to the presence of any one of a number of abnormal structures between the scapula and the chest wall, such as atrophied muscle,<sup>1</sup> fibrotic muscle,<sup>1,18</sup> and anomalous muscle insertions.

The most common bone lesion that may underlie scapulothoracic crepitus is the osteochondroma, arising from either the ribs or the scapula<sup>18-20</sup> (Fig. 3). Malunited fractures of the ribs or scapula are also capable of creating painful crepitus.<sup>1,18,21</sup> Abnormalities of the superomedial angle of the scapula, such as a hooked superomedial angle<sup>1,22</sup> and Luschnka's tubercle (which originally was described as an osteochondroma but has subsequently come to mean any prominence of bone at the superomedial angle<sup>1,22</sup>), have also been implicated

**Table 2**  
Causes of Symptomatic Scapulothoracic Crepitus

Interposed tissue
Muscle
Atrophy <sup>1,30</sup>
Fibrosis <sup>1,18</sup>
Anatomic variation <sup>30</sup>
Bone
Rib osteochondroma
Scapular osteochondroma <sup>19,20</sup>
Rib fracture <sup>18,21</sup>
Scapular fracture <sup>21</sup>
Hooked superomedial angle of scapula <sup>1,22</sup>
Luschnka's tubercle <sup>1</sup>
Reactive bone spurs from muscle avulsion <sup>17,23,24</sup>
Other soft tissues
Bursitis <sup>7-10</sup>
Tuberculosis lesions <sup>1</sup>
Syphilitic lesions <sup>1</sup>
Abnormalities in scapulothoracic congruence
Scoliosis <sup>18</sup>
Thoracic kyphosis <sup>1</sup>

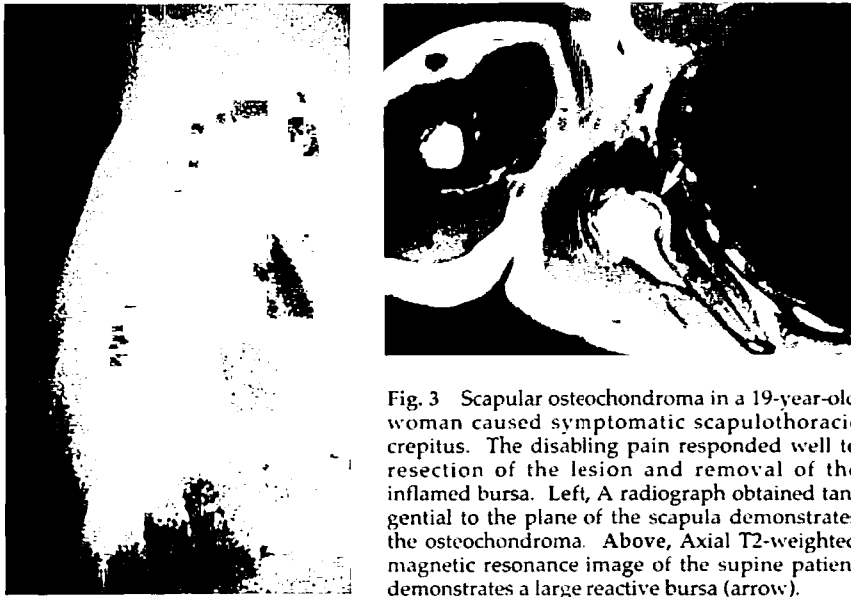


Fig. 3 Scapular osteochondroma in a 19-year-old woman caused symptomatic scapulothoracic crepitus. The disabling pain responded well to resection of the lesion and removal of the inflamed bursa. Left, A radiograph obtained tangential to the plane of the scapula demonstrates the osteochondroma. Above, Axial T2-weighted magnetic resonance image of the supine patient demonstrates a large reactive bursa (arrow).

as sources of scapulothoracic crepitus. Others implicate reactive spurs of bone that are created by the microtrauma of chronic, repeated periscapular muscle avulsions.<sup>11,17,23</sup>

Certainly, any bone lesion that causes scapulothoracic crepitus is capable of forming a reactive bursa,<sup>24,25</sup> and a bursa is frequently seen at the time of resection of such lesions. The bursa can become inflamed and painful even in the absence of a bone lesion and may become a source of crepitus. Pathologic changes in the soft tissues that have been implicated in scapulothoracic crepitus include tuberculous lesions in the scapulothoracic region and syphilitic lesions.<sup>1</sup>

Abnormalities in congruence of the scapulothoracic articulation are another source of scapulothoracic crepitus. Both scoliosis and thoracic kyphosis result in changes in congruence of this articulation and have been implicated as causes of scapulothoracic crepitus.

#### Diagnosis

The patient with symptomatic scapulothoracic crepitus may be able

to identify the source of the problem. A recent history of repetitive overhead activity, such as sports participation or wallpaper hanging, may be present.<sup>45</sup> Some authors suspect that there is a familial tendency toward developing symptoms.<sup>4</sup> Patients may also relate a history of trauma that precipitates symptoms.<sup>8</sup> Scapulothoracic crepitus is bilateral in some patients.<sup>11</sup>

Inspection of the scapula may reveal fullness or winging, which suggests a space-occupying lesion in the scapulothoracic space. Palpation or auscultation while the shoulder goes through the range of motion may help to identify the source of the periscapular crepitus.<sup>2,8</sup> The presence of a palpable mass, crepitus, prominence at rest, and normal scapulothoracic motion will help to differentiate scapular winging due to a physical mass from that resulting from neurologic scapular winging. In patients with scapulothoracic crepitus, the neuromuscular examination is frequently normal.

Tangential radiographic views of the scapula should be obtained in all cases to identify osseous ab-

normalities. In patients with suspected bone lesions not clearly seen on radiographs (such as a rib or scapular fracture), computed tomography may be helpful. A subtle variation in normal anatomy, such as a prominent superomedial angle of the scapula or a Luschka's tubercle, may not be well visualized with computed tomography or magnetic resonance imaging. Magnetic resonance imaging is helpful in identifying the size and location of the inflamed bursa.

#### Treatment

Nonoperative treatment should be attempted in patients with a clearly defined bone lesion, such as an osteochondroma; however, these patients are unlikely to benefit.<sup>1</sup> Resection of the bone lesion is usually necessary to alleviate symptoms, and surgical intervention under those circumstances is associated with a high likelihood of success.<sup>18,20,26</sup> For other patients, a trial of conservative treatment is appropriate. Nonoperative treatment seems to be most beneficial if a soft-tissue disorder is the source of scapulothoracic crepitus.<sup>1,2</sup>

Poor posture is an important contributor to the development of scapulothoracic crepitus. Therefore, nonoperative treatment should include postural exercises designed to strengthen the upper thoracic musculature so as to prevent sloping of the shoulders.<sup>2,27</sup> In addition, a figure-of-eight harness may be worn while awake, serving as a reminder to seek to attain normal posture. Exercises to strengthen periscapular muscles are also thought to be important.<sup>1,2,5</sup> These should include exercises to increase the bulk of the subscapularis and serratus anterior in an attempt to increase the space between the scapula and the chest wall.

Systemic nonsteroidal anti-inflammatory drugs; local modalities, such as heat, massage, phono-

phoresis, and ultrasound; and the application of ethyl chloride to trigger points may also prove useful in alleviating pain.<sup>1,2,5</sup> Injection of local anesthetics and corticosteroids into the painful area has also been recommended.<sup>1,4,5,10,11</sup> Caution must be used, however, as there is a risk of creating a pneumothorax.<sup>11</sup> When these are used, most patients have a marked decrease in pain.<sup>5,10</sup>

A number of surgical options have been described when nonoperative treatment is not successful. Historically, musculoplasty operations include those described in 1904 by Mauclair, who reflected a flap of the rhomboids or trapezius and sutured it to the undersurface of the scapula. This is thought to be inadequate, however, because

the muscle flap may atrophy with time, and symptoms can recur.<sup>1</sup> Rockwood reported that excising a rhomboid muscle avulsion flap resulted in the elimination of snapping and pain.<sup>11</sup> The results of musculoplasty operations have been variable, and as a result partial scapulectomy has become a widely used means of treating symptomatic scapulothoracic crepitus. Although Cameron<sup>28</sup> has reported that resection of the medial border of the scapula produces good results, resection of the superomedial angle of the scapula is the more common approach.<sup>1,4,22,23,29,30</sup>

The surgical technique for the resection of the superomedial border of the scapula begins with the patient in the prone position (Fig. 4). An incision based over the medial

spine of the scapula is made, and the soft tissue is dissected down to the spine of the scapula. The periosteum over the spine is incised, and the supraspinatus, rhomboid, and levator scapulae muscles are dissected free of the scapula in a subperiosteal plane. The superomedial angle of the scapula is resected with an oscillating saw. As the resection is carried laterally, caution is warranted to avoid injury to the dorsal scapular artery and the suprascapular nerve in the suprascapular notch. After resection of the bone, the reflected muscles fall back into place, and the periosteum is reapproximated to the spine of the scapula by suturing through drill holes. Postoperatively, the patient is placed in a sling and begins passive motion immediately. Active

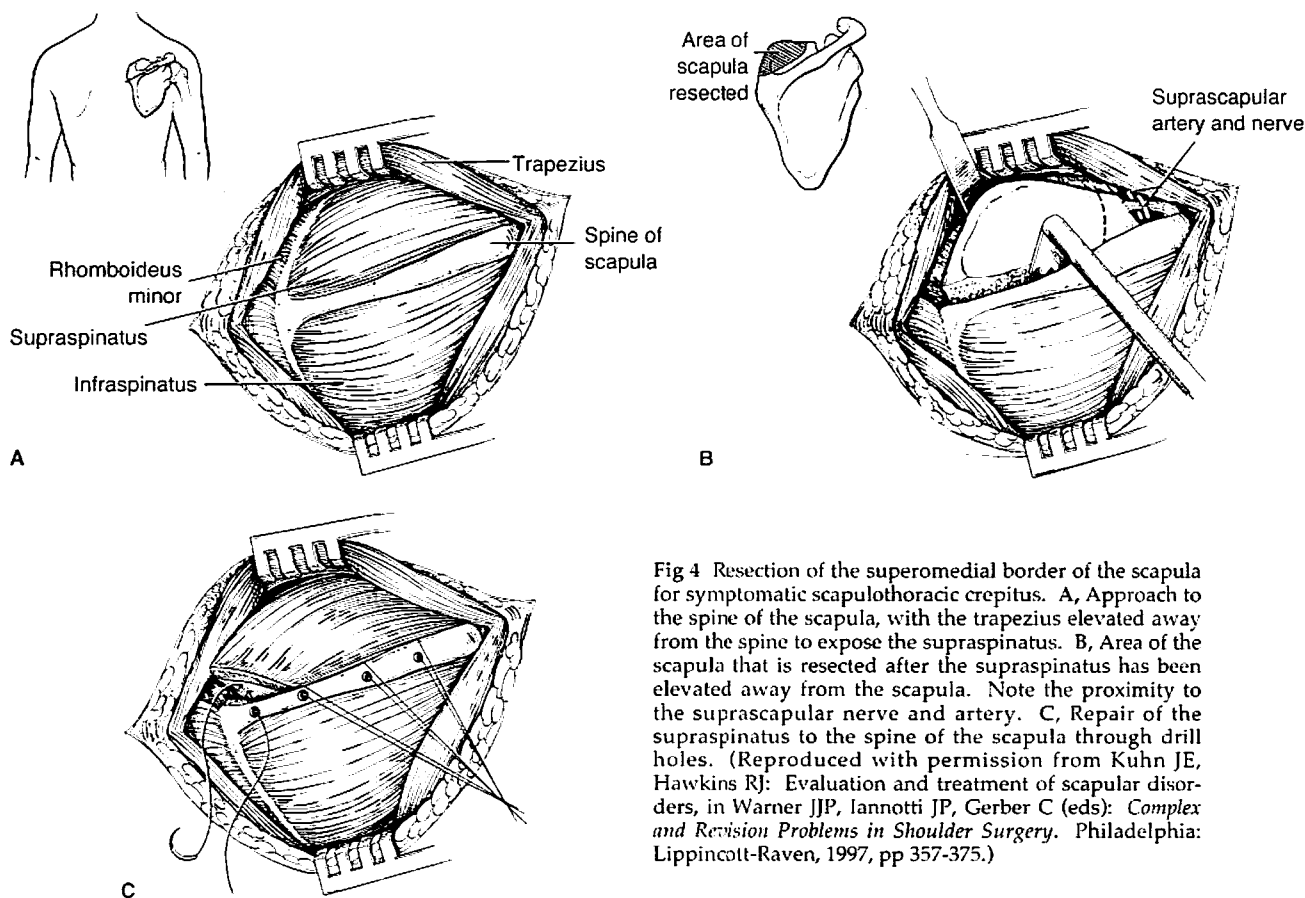


Fig 4 Resection of the superomedial border of the scapula for symptomatic scapulothoracic crepitus. A, Approach to the spine of the scapula, with the trapezius elevated away from the spine to expose the supraspinatus. B, Area of the scapula that is resected after the supraspinatus has been elevated away from the scapula. Note the proximity to the suprascapular nerve and artery. C, Repair of the supraspinatus to the spine of the scapula through drill holes. (Reproduced with permission from Kuhn JE, Hawkins RJ: Evaluation and treatment of scapular disorders, in Warner JJP, Iannotti JP, Gerber C (eds): *Complex and Revision Problems in Shoulder Surgery*. Philadelphia: Lippincott-Raven, 1997, pp 357-375.)

motion is begun at 8 weeks, and resistance exercises follow at 12 weeks.

Although some authors report mixed results with this procedure,<sup>11</sup> most others suggest that it is an excellent treatment option.<sup>1,4,22,29</sup> However, to date most of these reports have been from case studies or very small series. Arntz and Matsen<sup>8</sup> describe their results after resection of the superomedial border of the scapula in 14 shoulders in 12 patients with a 42-month follow-up. In their series, complete relief of pain and crepitus was obtained in 12 (86%) of 14 shoulders. It is

important to note that the bone resected appears normal on gross and histologic examination, which has prompted some to perform bursectomy and avoid a partial scapulectomy<sup>7</sup> and has led others to believe that releasing a fibrotic or spastic levator scapulae may be the important element in relieving symptoms.

### Summary

The understanding and treatment of scapulothoracic disorders, particularly symptomatic scapulothoracic crepitus, continues to evolve.

Clearly, nonoperative treatment is the best approach for the patient with symptomatic scapulothoracic crepitus. If an appropriate trial of conservative treatment is unsuccessful, surgery can produce satisfactory results. Although many authors recommend resection of the superomedial border of the scapula and have had good outcomes, the lack of pathologic tissue changes has prompted others to perform open bursectomy without partial scapulectomy. Recently, arthroscopic techniques have been investigated, and early experience suggests that they may be safe and effective.

### References

- Milch H: Snapping scapula. *Clin Orthop* 1961;20:139-150.
- Ciullo JV, Jones E: Subscapular bursitis: Conservative and endoscopic treatment of "snapping scapula" or "washboard syndrome." *Orthop Trans* 1992-1993;16:740.
- Kolodychuk LB, Reagan WD: Visualization of the scapulothoracic articulation using an arthroscope: A proposed technique. *Orthop Trans* 1993-1994; 17:1142.
- Cobey MC: The rolling scapula. *Clin Orthop* 1968;60:193-194.
- Percy EC, Birbrager D, Pitt MJ: Snapping scapula: A review of the literature and presentation of 14 patients. *Can J Surg* 1988;31:248-250.
- Codman EA: *The Shoulder*. Malabar, Fla: Krieger Publishing, 1984, pp 1-31.
- Sisto DJ, Jobe FW: The operative treatment of scapulothoracic bursitis in professional pitchers. *Am J Sports Med* 1986;14:192-194.
- Arntz CT, Matsen FA III: Partial scapulectomy for disabling scapulothoracic snapping. *Orthop Trans* 1990;14: 252-253.
- McCluskey GM III, Bigliani LU: Surgical management of refractory scapulothoracic bursitis. *Orthop Trans* 1991; 15:801.
- McCluskey GM III, Bigliani LU: Scapulothoracic disorders, in Andrews JR, Wilk KE (eds): *The Athlete's Shoulder*. New York: Churchill Livingstone, 1994, pp 305-316.
- Butters KP: The scapula, in Rockwood CA Jr, Matsen FA III (eds): *The Shoulder*. Philadelphia: WB Saunders, 1990, pp 335-366.
- Gillogly SD, Bizousky DT: Arthroscopic evaluation of the scapulothoracic articulation. *Orthop Trans* 1992-1993;16:196.
- Grünfeld G: Beitrag zur Genese des Skapularkrachens und der Skapulargeräusche. *Arch Orthop* 1927;24:610-615.
- Moseley HF: *Shoulder Lesions*, 2nd ed. New York: Paul B. Hoeber, 1953, pp 211-213.
- Neer CS II: *Shoulder Reconstruction*. Philadelphia: WB Saunders, 1990, pp 421-485.
- Shull JR: Scapulocostal syndrome: Clinical aspects. *South Med J* 1969;62:956-959.
- Bateman JE: *The Shoulder and Neck*, 2nd ed. Philadelphia: WB Saunders, 1978, pp 185-194.
- Milch H: Partial scapulectomy for snapping of the scapula. *J Bone Joint Surg Am* 1950;32:561-566.
- Milch H, Burman MS: Snapping scapula and humerus varus: Report of six cases. *Arch Surg* 1933;26:570-588.
- Parsons TA: The snapping scapula and subscapular exostoses. *J Bone Joint Surg Br* 1973;55:345-349.
- Steindler A: *The Traumatic Deformities and Disabilities of the Upper Extremity*. Springfield, Ill: Charles C Thomas, 1946, pp 112-118.
- Richards RR, McKee MD: Treatment of painful scapulothoracic crepitus by resection of the superomedial angle of the scapula: A report of three cases. *Clin Orthop* 1989;247:111-116.
- Strizak AM, Cowen MH: The snapping scapula syndrome: A case report. *J Bone Joint Surg Am* 1982;64:941-942.
- Cuomo F, Blank K, Zuckerman JD, Present DA: Scapular osteochondroma presenting with exostosis bursata. *Bull Hosp Jt Dis* 1993;52:55-58.
- Shogry MEC, Armstrong P: Case report 630: Reactive bursa formation surrounding an osteochondroma. *Skeletal Radiol* 1990;19:465-467.
- Morse BJ, Ebraheim NA, Jackson WT: Partial scapulectomy for snapping scapula syndrome. *Orthop Rev* 1993; 22:1141-1144.
- Michele AA, Davies JJ, Krueger FJ, Lichtor JM: Scapulocostal syndrome (fatigue-postural paradox). *N Y State J Med* 1950;50:1353-1356.
- Cameron HU: Snapping scapulae: A report of three cases. *Eur J Rheumatol Inflamm* 1984;7:66-67.
- Kouvalchouk JF: Subscapular crepitus. *Orthop Trans* 1985;9:587-588.
- Wood VE, Verska JM: The snapping scapula in association with the thoracic outlet syndrome. *Arch Surg* 1989;124:1335-1337.